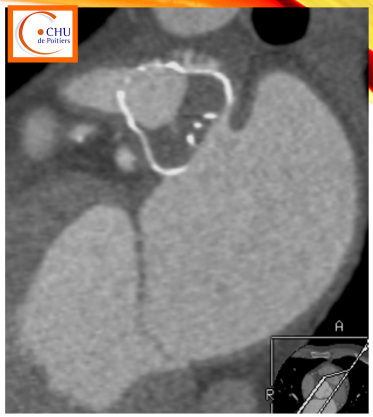

AURICULE GAUCHE EN SCANNER

Pr Luc Christiaens
Cardiologie
CHU de Poitiers

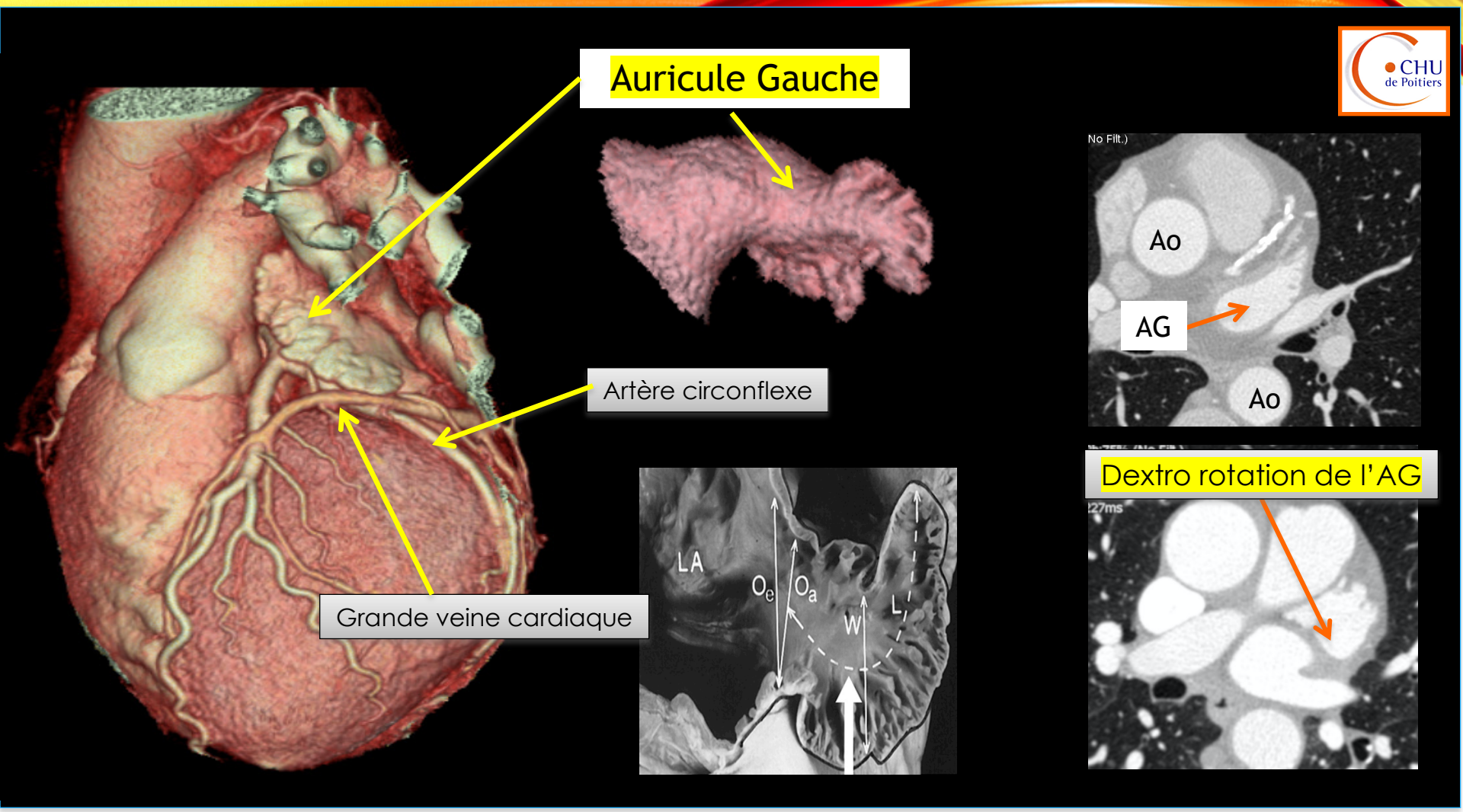

Ostium anatomique: (Oa)

transition entre la paroi lisse de l'OG et la partie trabéculée de l'AG

Landmesser U, Eur H J 2011

Ostium échographique: (Oe)

ligne entre la VPSG et la junction inférieure de l'OG et de l'AG

ANATOMIE DE L'AG ++

- Lobes:
  - 1 lobe (20%–70%), 2 lobes (16%–54%), parfois 4 lobes
  - horn-shaped (ostium plus large que le corps de l'AG) augmente le risque d'embolisation
  - parallel tube (ostium et corps de même calibre)
  - angel wing (ostium plus petit que le corps)

- Ostium:
  - Formes variées: elliptique dans 69%
  - dimensions: 22 ±4mm (12–39 mm)

- Epaisseur de la paroi: 1 mm

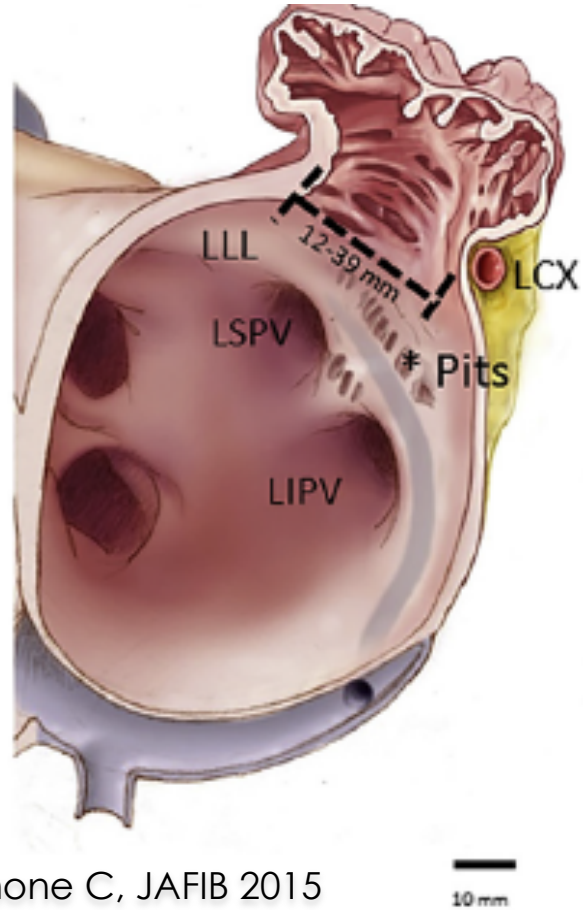

Naksuk N, J Am Coll Cardiol EP 2016. DeSimone C, JAFIB 2015

ANATOMIE AURICULE GAUCHE ++

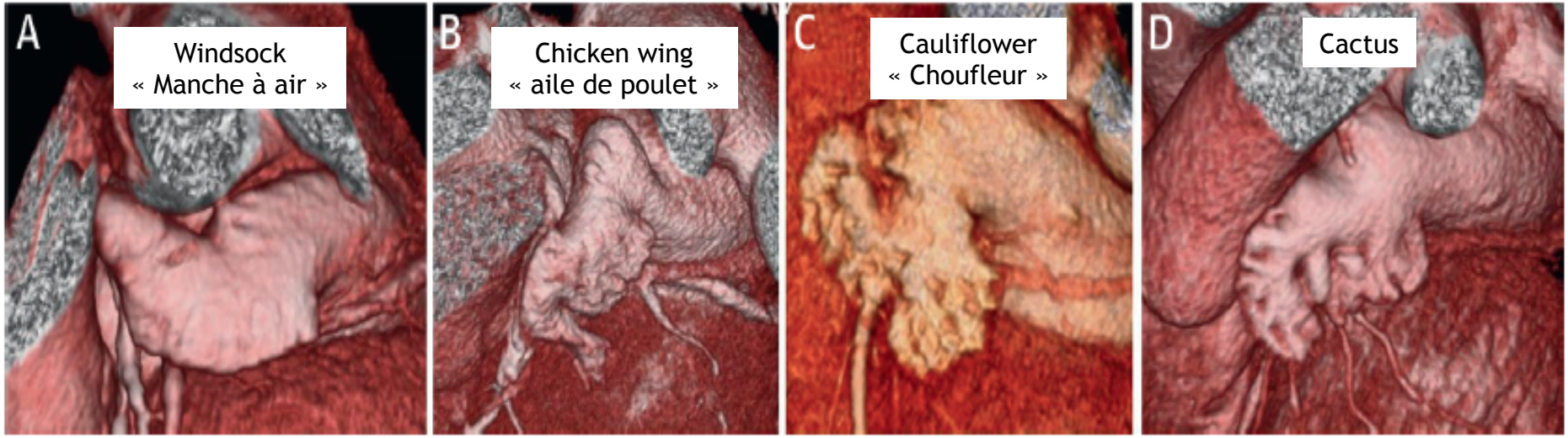

The classification of the left atrial appendage (LAA) morphology is based on the shape of the central and secondary lobes: windsock **(A)** (with 1 central lobe), chicken wing **(B)** (with a central lobe bended), cauliflower **(C)** (when the central lobe is short and with several lobes leading to a distal width larger than the proximal part), and cactus **(D)** (with a central lobe leading to several secondary lobes superior and inferiorly).

JACC VOL. 70, NO. 25, 2017
DECEMBER 26, 2017:3157–72

Delgado *et al.*
LA and LAA: Implications for AF and Stroke

RISQUE EMBOLIQUE ET ANATOMIE AG

Meta-analyse de 8 études et 2,596 patients en FA:

La morphologie en “chicken wing” de l’AG est associée à un moindre risqué d’événement thromboembolique / autres morphologies
(odds ratio: 0.46; 95% confidence interval: 0.36 to 0.58)

Luperdo F, Heart Rhythm 2016

"cauliflower" LAA: main lobe of less than 4cm long without forked lobes significantly more common in patients with stroke (OR 3.857;95% CI 1.482–10.037; P = .005).

CHA2DS2-VASc score-adjusted logistic regression analysis :
cauliflower LAA = independent predictor of a stroke (OR 3.35-5 ; 95% CI 1.243–9.055; P = .017)

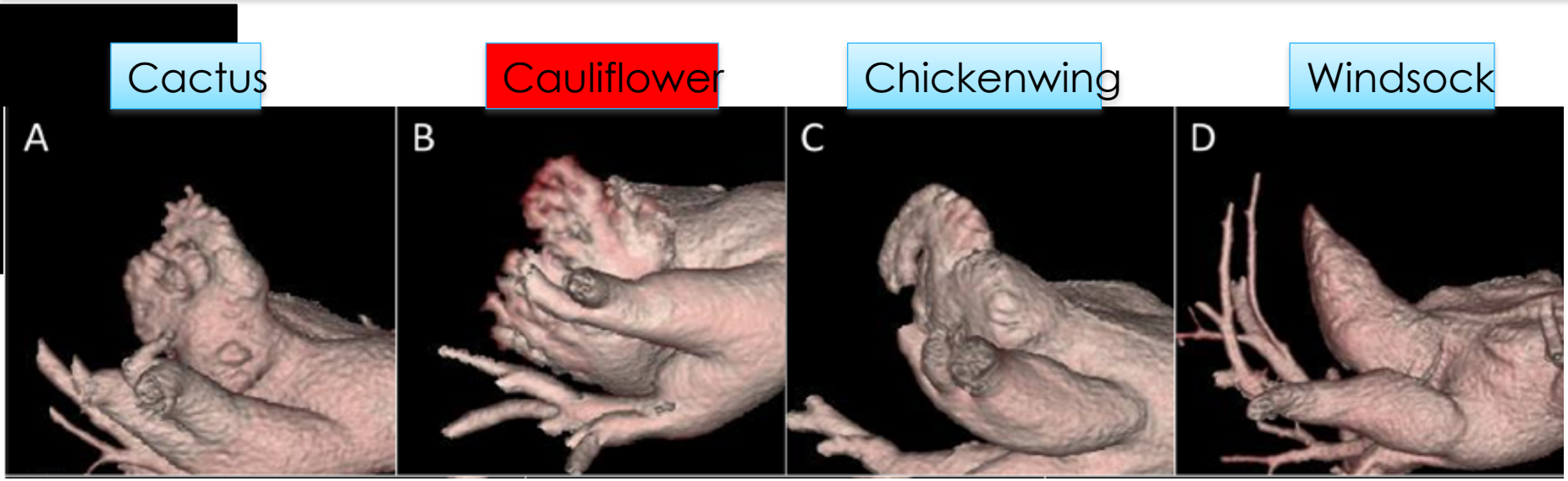

LAA volume				
13.6 ± 5.9	13.1 ± 4.7	19.9 ± 10.1	17.9 ± 7.6	.01

Kimura T, Heart Rhythm 2013;10: 922

SCANNER ET THROMBUS DANS L'AG ++

- AG: siege de 91% des thrombi en cas de FANV

- Piège: Thrombus ou mélange incomplet du produit de contraste dans l'AG ?

  - 2 acquisitions (++): scanner injecté standard + temps tardif (au 30 à 60 secondes après l'injection)
    - sensitivité 100% spécificité : 99%
    - VPN : 100% VPP : 92% Accuracy : 99%

  - 1 acquisition:
    - 3 bolus de pdc: 50-mL puis 180-secondes plus tard 50 mL puis 70 mL

Saw J, Can J Cardiol 2016

Romero J, Circ Cardiovasc Imaging. 2013;6:185-194

STASE OU THROMBUS DANS AURICULE G

LAA / LA < 0.39 : risque d'embol
Sensibilité: 71%
Spécificité: 90%

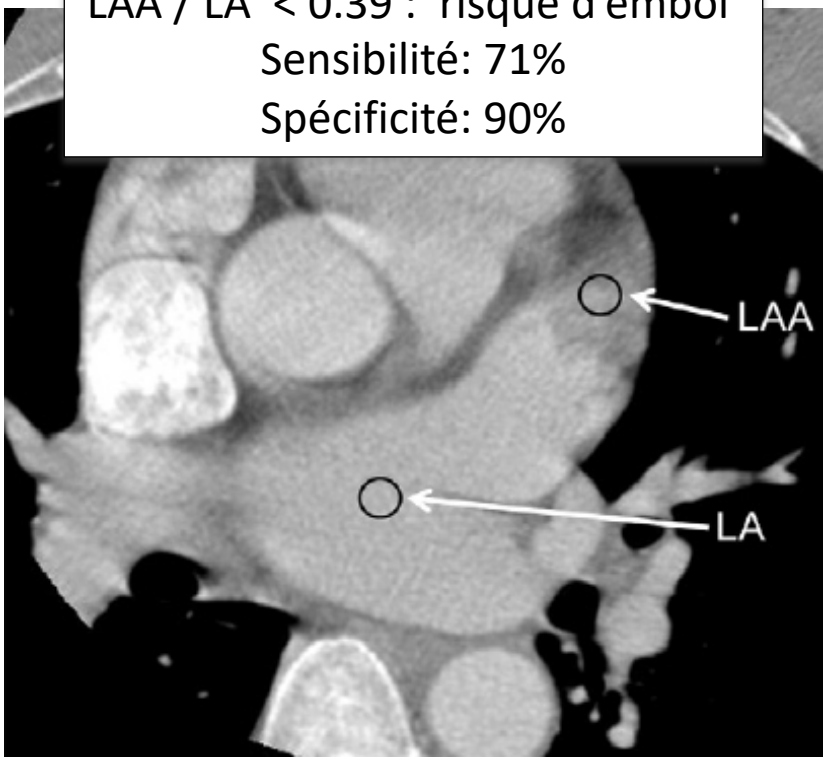

N. Funabashi et al. / International Journal of Cardiology 185 (2015) 297–300

Thrombus circonscrit par PdC
Temps tardif inutile

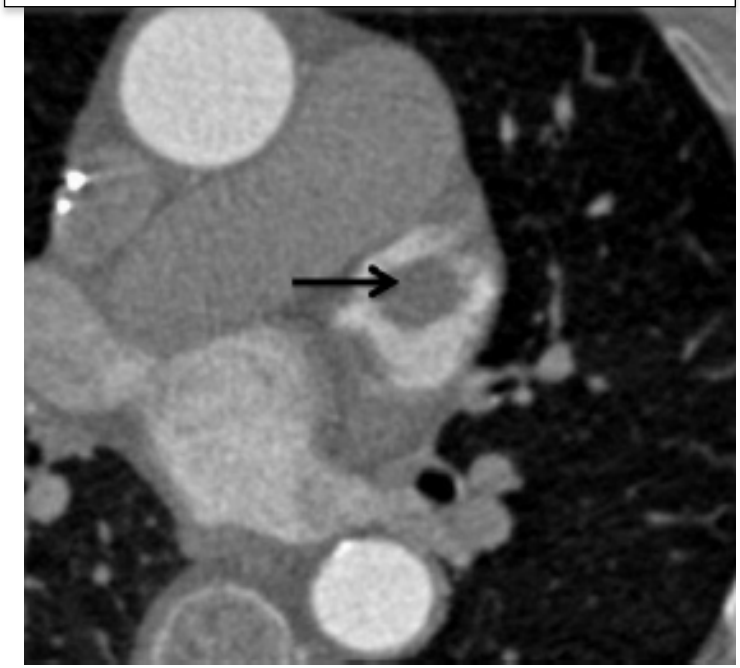

Ismail TF, JCCT 2015

Detection of Left Atrial Appendage Thrombus by Cardiac Computed Tomography in Patients With Atrial Fibrillation

A Meta-Analysis

Jorge Romero, MD; Syed Arman Husain, MD; Iosif Kelesidis, MD; Javier Sanz, MD; Hector M. Medina, MD; Mario J. Garcia, MD

Circ Cardiovasc Imaging. 2013;6:185-194.

TDM vs ETO patients avec bilan AVC ou pré ablation de FA.
Tous avec ACFA permanente ou paroxystique
19 études, 2955 patients, 71% hommes, 61 ± 4 ans

Incidence LAA/LA thrombus: 8.9 ± 7%

Sensibilité :	96%	100% si temps tardif
Spécificité:	92%	99%
VPP:	41%	92%
VPN:	99%	100%
Accuracy:	94%	99%

Défaut de remplissage

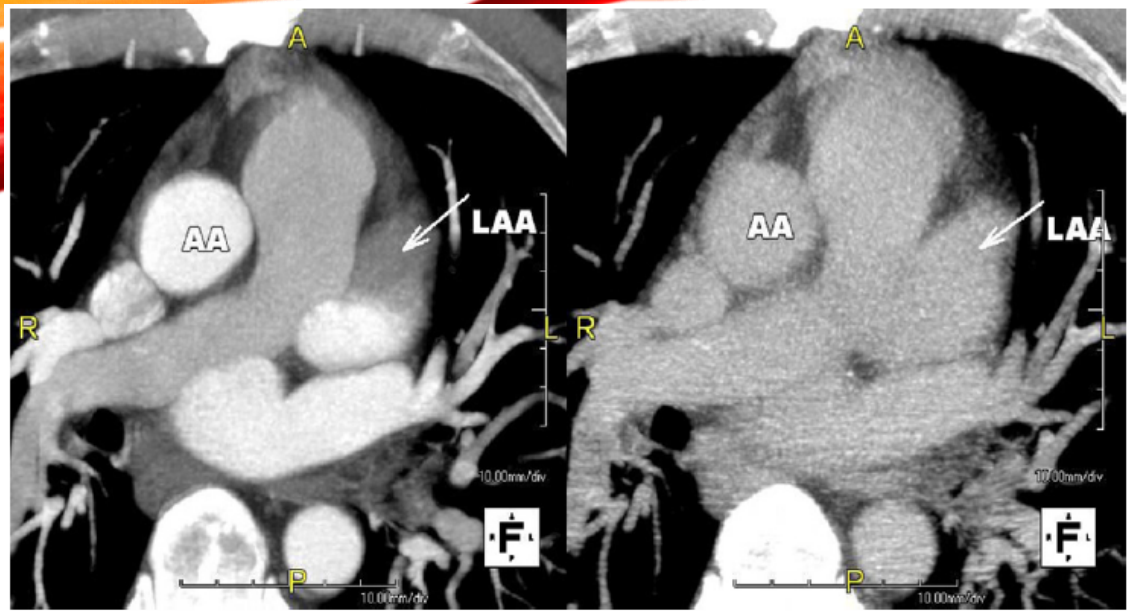

Temps tardif: 80 -100 KV à 1 minute

Thrombus dans l'auricule G

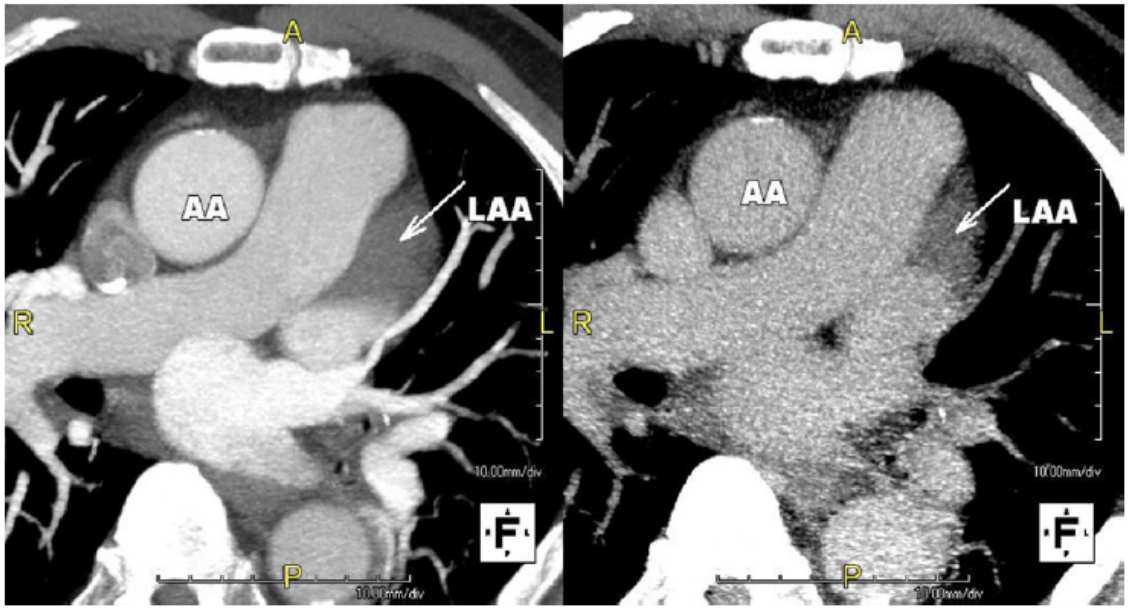

Sawit ST, Am J Cardiol 2012;109:677-684

Scanner injecté temps artériel

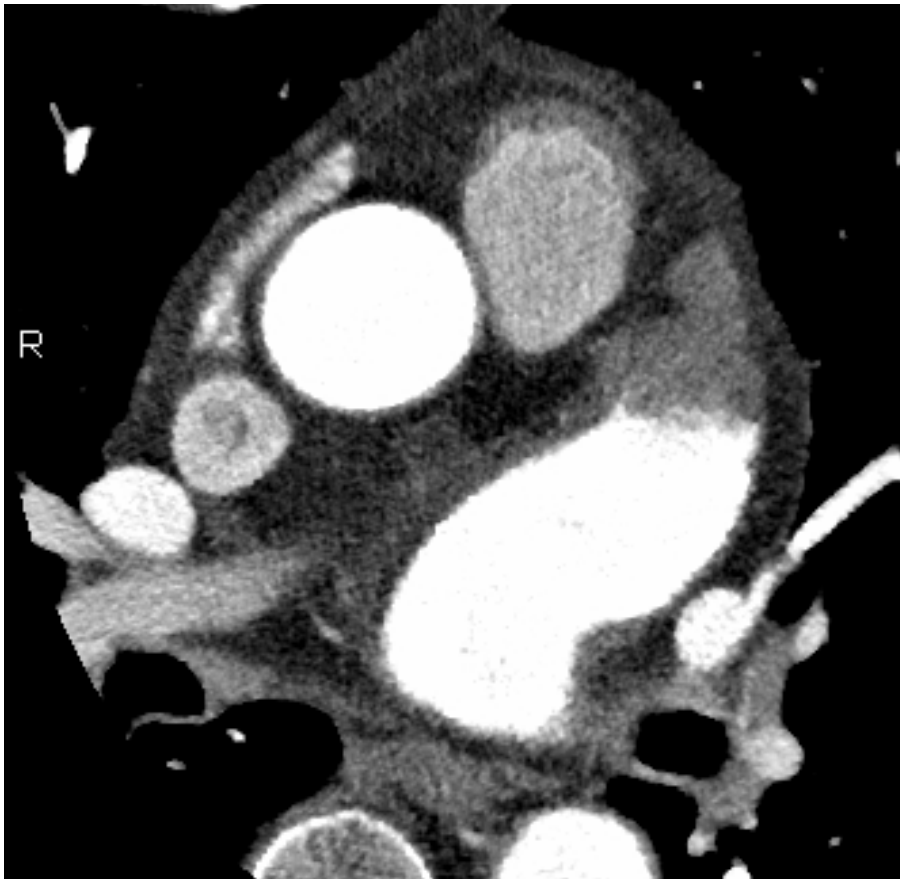

Scanner injecté temps tardif

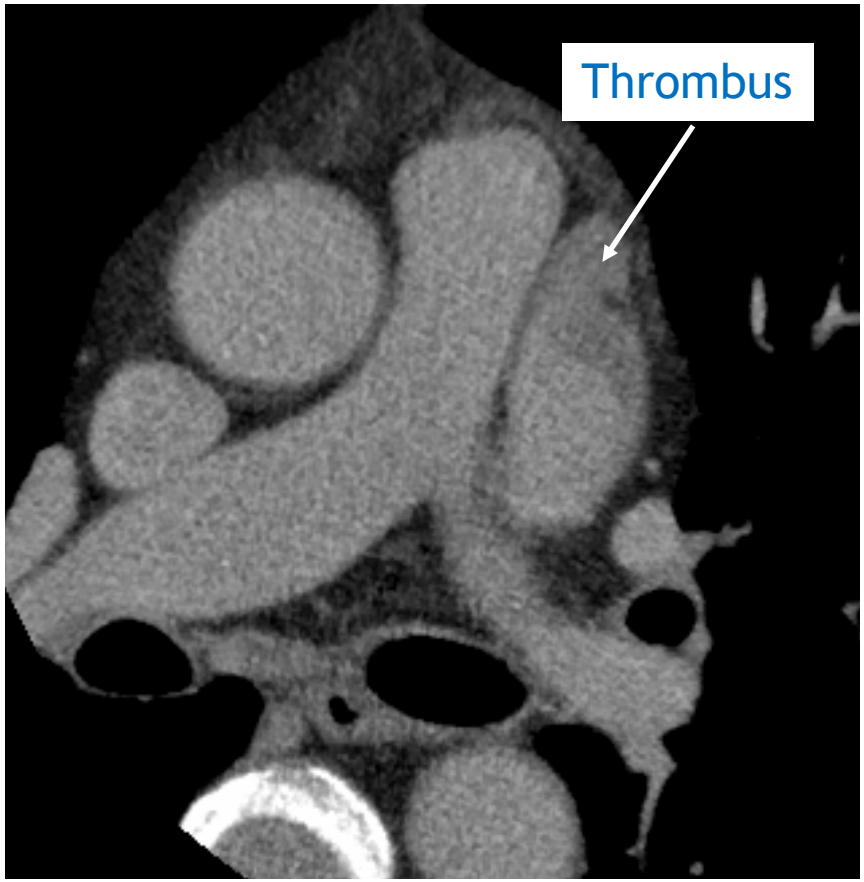

Occlusion or exclusion of the left atrial appendage

Recommendations	Class	Level
After surgical occlusion or exclusion of the LAA, it is recommended to continue anticoagulation in at-risk patients with AF for stroke prevention.	I	B
LAA occlusion may be considered for stroke prevention in patients with AF and contra-indications for long-term anticoagulant treatment (e.g. those with a previous life-threatening bleed without a reversible cause).	IIb	B
Surgical occlusion or exclusion of the LAA may be considered for stroke prevention in patients with AF undergoing cardiac surgery.	IIb	B
Surgical occlusion or exclusion of the LAA may be considered for stroke prevention in patients undergoing thoracoscopic AF surgery.	IIb	B

European Heart Journal - doi:10.1093/eurheartj/ehw210

EUROPEAN SOCIETY OF CARDIOLOGY®

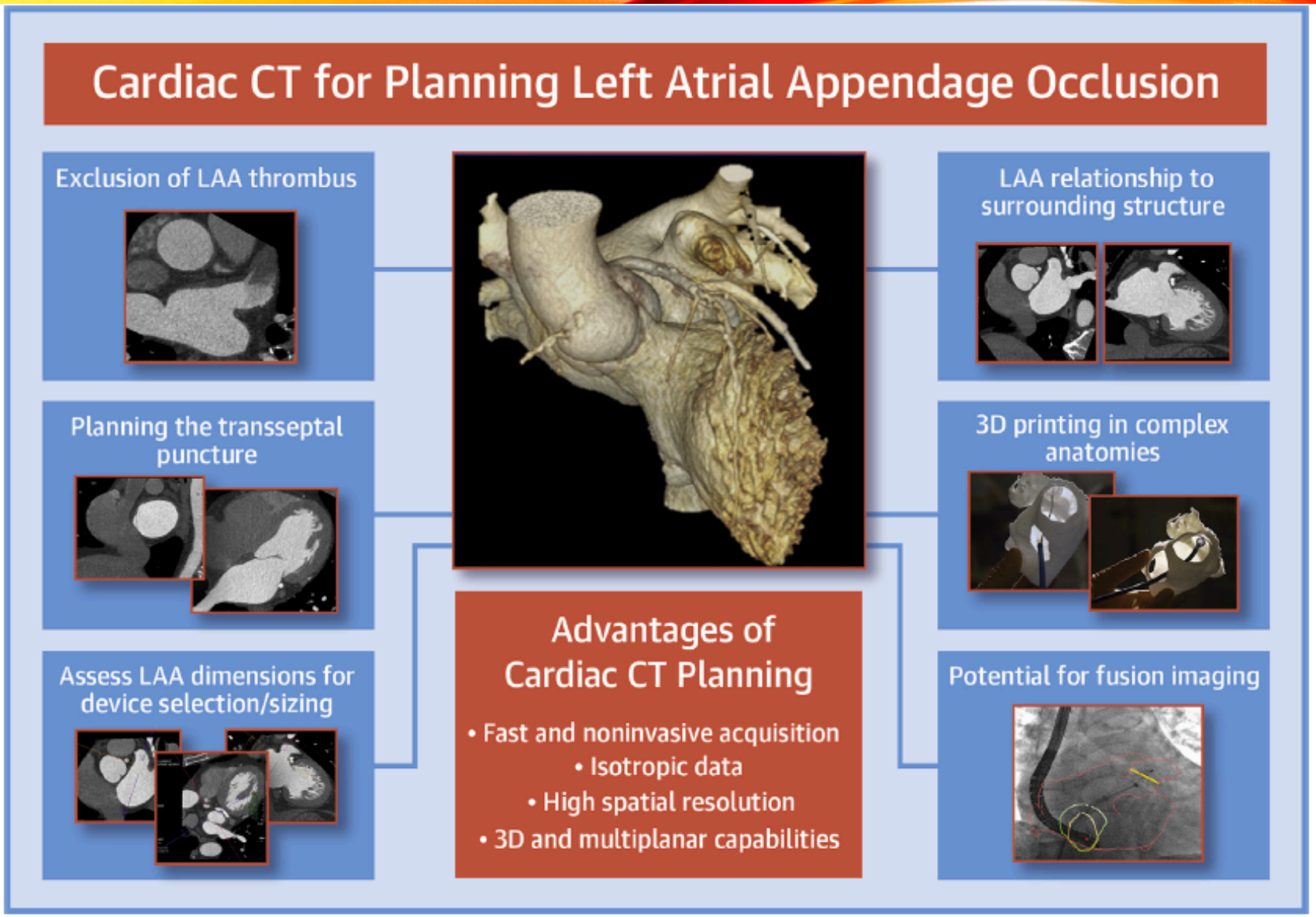

Korsholm, K. et al. J Am Coll Cardiol Intv. 2020;13(3):277–92.

Les techniques de réalisation en fonction du scanner et les points à rapporter dans le compte rendu sont précisés dans cet article

DISPOSITIFS D'OCCLUSION D'AG

- Watchman™ Boston Scientific
  - nitinol
  - 5 tailles: 21, 24, 27, 30, and 33 mm diametre, longeur 20,2 à 31,5mm
  - Pour diamètre AG: 17 à 31mm
  - Choix de la prothèse: 10 à 20% plus large que le diamètre de l'AG

- Watchman FLX™
  - Temporairement stoppé (embolisation)
  - 5 tailles: 20-35mm

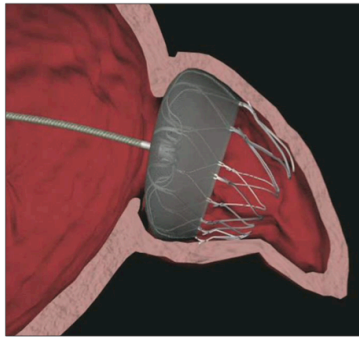

Auricule G 2020 christiaens

- Amplatzer Cardiac Plug 1 (ACP) ™ St Jude Medical
  - 16-30mm (8 tailles)

- Amplatzer Cardiag Plug 2 AMULET™
  - 8 tailles (16-34mm)
  - Diamètre AG zone de largage: 11-31mm, profondeur du lobe principal > 10-12mm

Feature	ACP								Amulet							
Sizes (mm)	16	18	20	22	24	26	28	30	16	18	20	22	25	28	31	34
Disc Diameter	Lobe + 4 mm				Lobe + 6 mm				Lobe + 6 mm				Lobe + 7 mm			
Lobe Length	6.5 mm								7.5 mm				10 mm			
Waist Length	4 mm								5.5 mm				8 mm			
Sheath Diameter	9Fr	10Fr			13Fr				12Fr							14Fr
Stabilizing Wires	6 pairs								6 pairs		8 pairs			10 pairs		

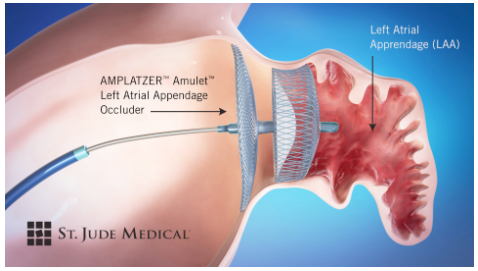

AMPLATZER(TM) Amulet(TM)

Tzikas A, Eurointervention 2016

AMPLATZER™ Amulet™

Left atrial appendage occluder

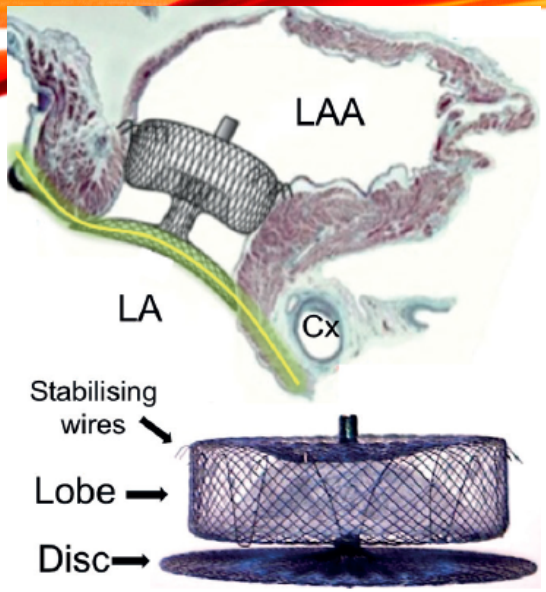

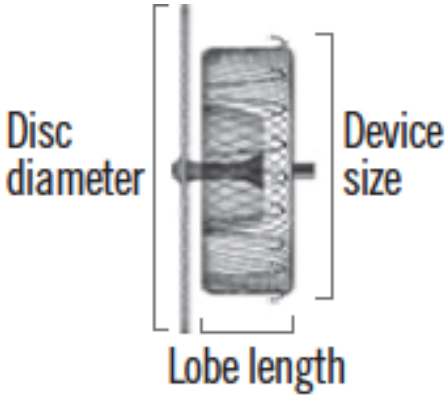

Device dimensions and sizing chart

Maximum landing zone width (mm)	Device size (mm)	Lobe length (mm)	Minimum LAA depth (mm)	Disc diameter (mm)	Sheath diameter
11.0-13.0	**16**	7.5	≥10	22	12 Fr or 14 Fr (with adaptor)
13.0-15.0	**18**	7.5	≥10	24	
15.0-17.0	**20**	7.5	≥10	26	
17.0-19.0	**22**	7.5	≥10	28	
19.0-22.0	**25**	10	≥12	32	
22.0-25.0	**28**	10	≥12	35	14 Fr
25.0-28.0	**31**	10	≥12	38	
28.0-31.0	**34**	10	≥12	41	

Auricule G 2020 christiaens

SCANNER ET OCCLUSION DE L'AG

- Anatomie du SIA
- Anatomie de l'AG
- Forme et taille de la landing zone
- Attention
  - si sinusal (RR 30-40%), ACFA, pression de remplissage OG (>10mmHg, si nécessaire 500ml perfusion de sérum physiologique avant le tdm)

"CHALLENGING" ANATOMIES DE L'AG

- Chicken wing: coubure proximale (<10 mm /ostium) >90°

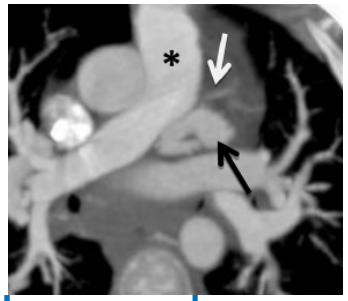

Auricule G rétro PA
Souvent difficile

Ismail TF, JCCT 2015

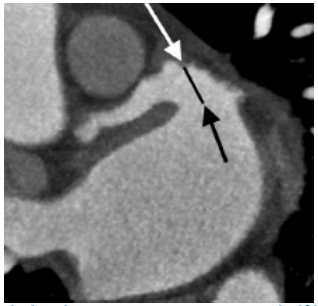

- Horn-shaped (+ difficile) / parallel tube ou angel-like wing (+ facile)
- Profondeur du lobe principal (% dispositif)
- Muscles pectinés protubérants
- Lobes additionnels

Franczr YK, 2015
J CV Computed Tomog

Sizing for Watchman™ mesure du diamètre

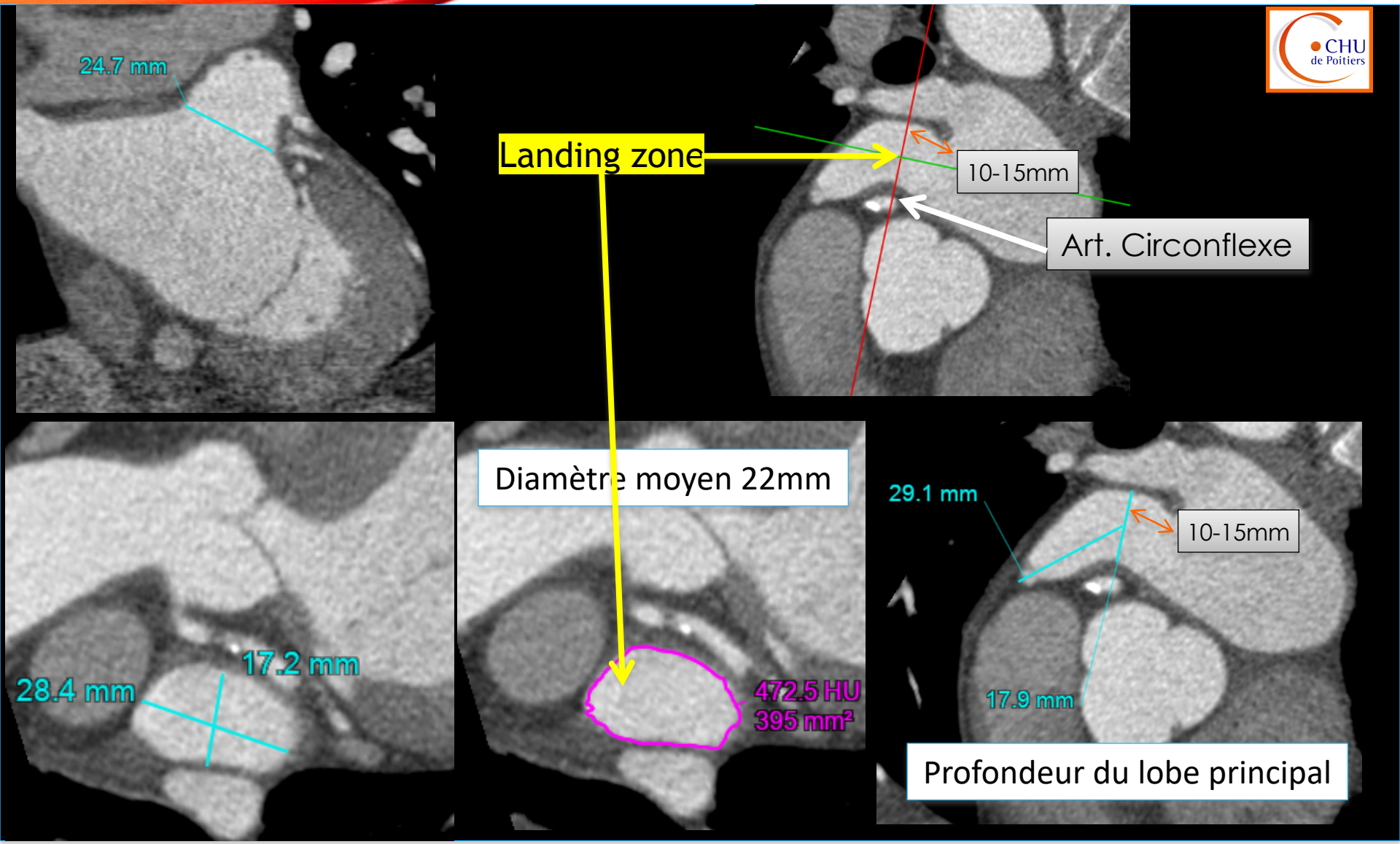

Sizing for AMULET™ device: Mesure de diamètre et de longueur !

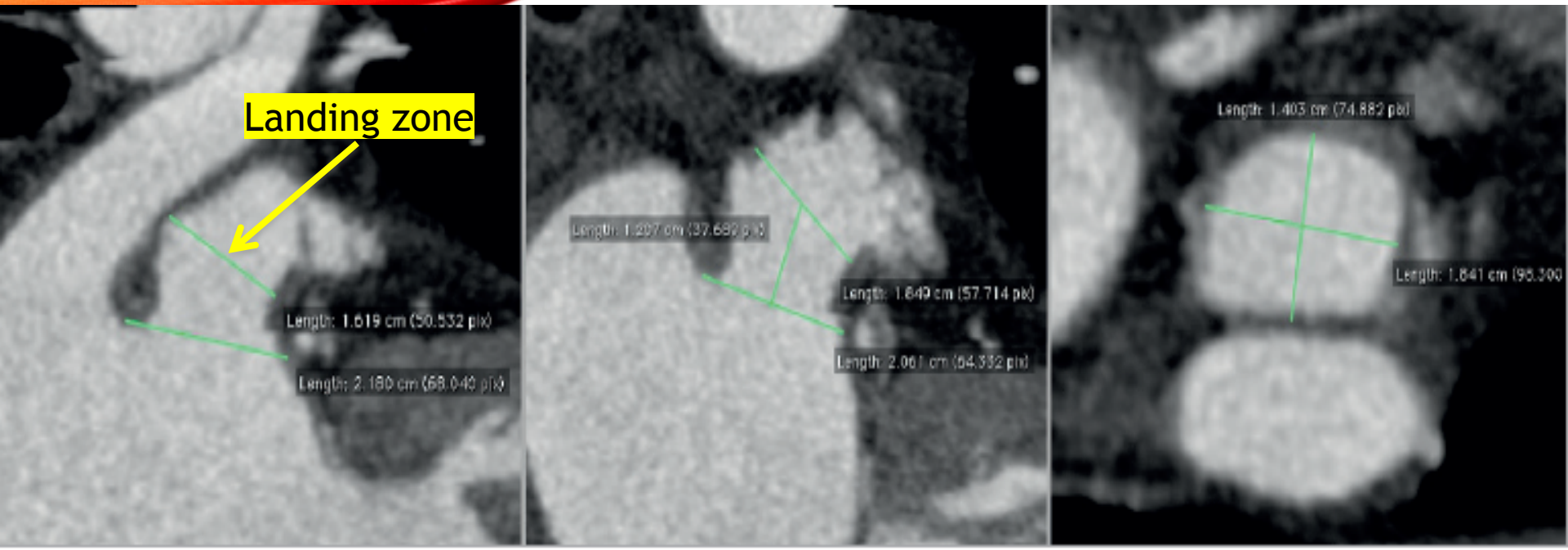

Landing zone: à 12-15mm de l'ostium de l'AG (10mm pour ACP™) mesure du diamètre moyen ou maximal (cf. Amulet sizing chart)

Profondeur minimale du lobe principal : Amulet de 16 à 22 mm: 7.5 mm, Amulet de 25 à 34 mm: profondeur minimale 10 mm

Tzikas A, Eurointervention 2016

Device sizing for AMULET implantation

1. ***Orifice*** (***OR***) is defined as a line connecting the left upper pulmonary vein ridge and the circumflex coronary artery (*echocardiographic orifice*)
2. ***Device landing zone*** (***LZ***) is positioned 10-12 mm inside the LAA, from the orifice, and perpendicular to the LAA wall.
3. ***Depth*** of the appendage is measured as a central, perpendicular line from the OR to the roof of the appendage (***blue line***)

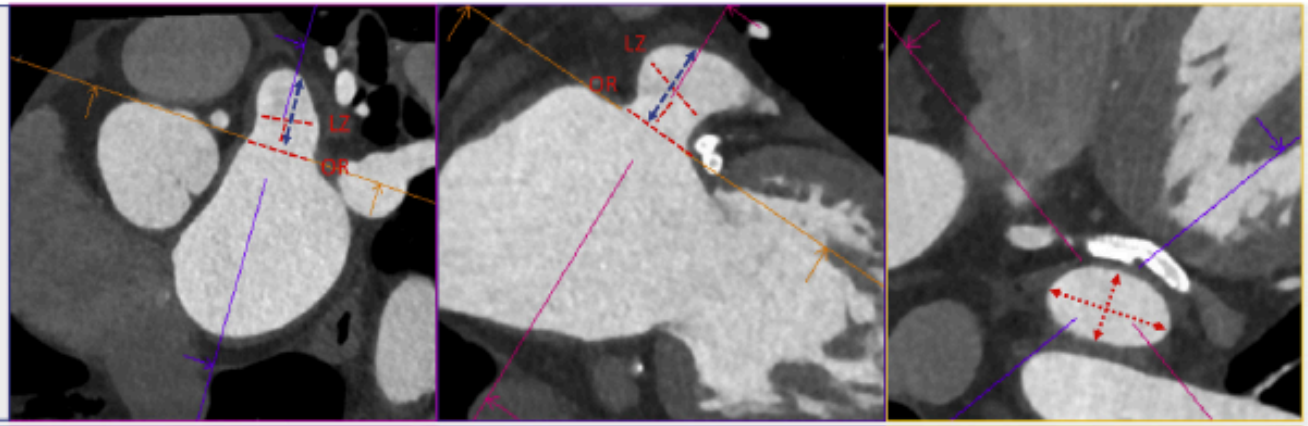

Device sizing for WATCHMAN implantation

1. ***Device landing zone*** (***LZ***) is defined as a line connecting the circumflex coronary artery and a point 1-2 cm inside the LAA, measured from the left upper pulmonary ridge tip.
2. ***Length/depth*** of the appendage is measured as a line from the landing zone to the most distal tip of the appendage (***blue line***).

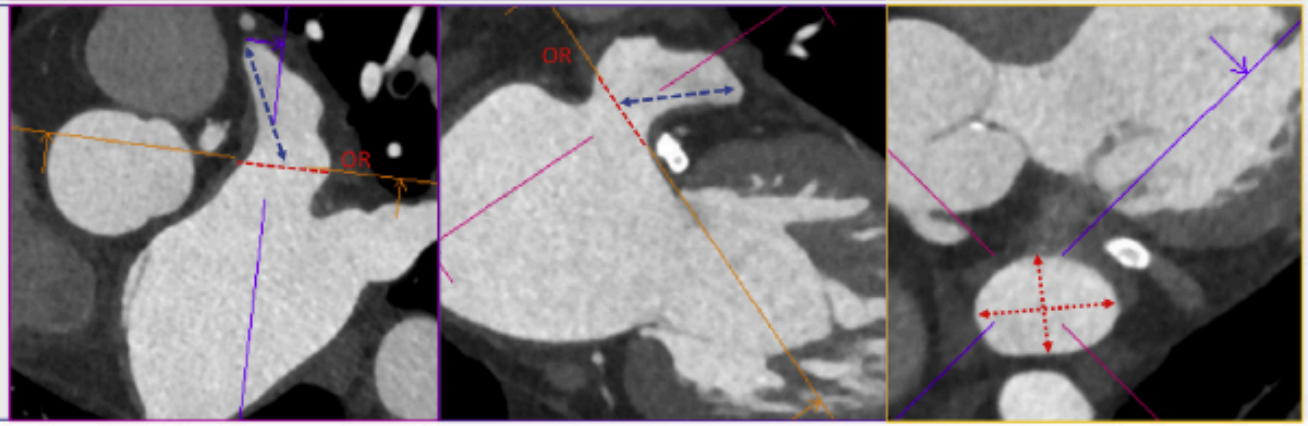

Korsholm, K. et al. J Am Coll Cardiol Intv. 2020;13(3):277-92.

SIZING

- Watchman™:
  - 10-25% > diamètre max de la landing zone (+2-4mm)
  - Profondeur du lobe principal > diamètre maximal
- ACP™:
  - + 3 - 5mm / diamètre maximal
  - Profondeur de lobe > 10mm
- Amulet™:
  - + 2 - 4mm / diamètre maximal
  - < 5 mm / diamètre minimal
  - Profondeur de lobe > 12-15mm

SUR MESURE …

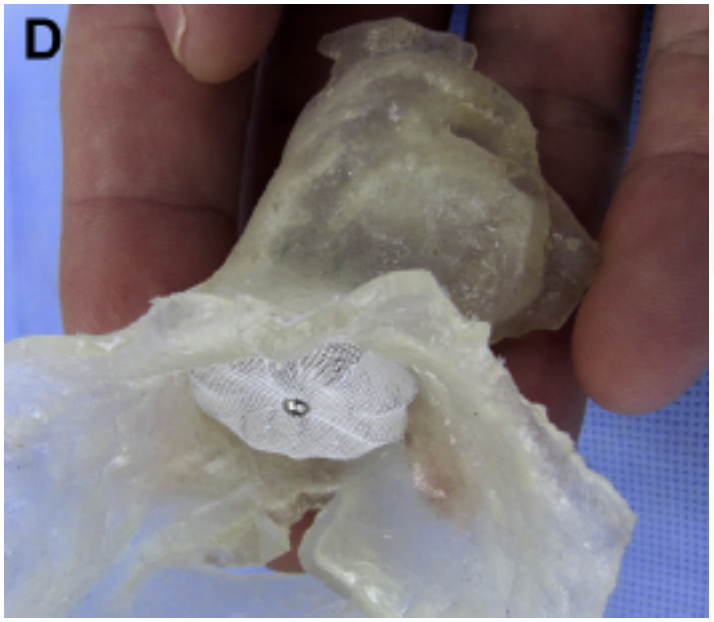

Modèle 3D à partir des données du scanner

Otton JM, 2015 JACC CVi

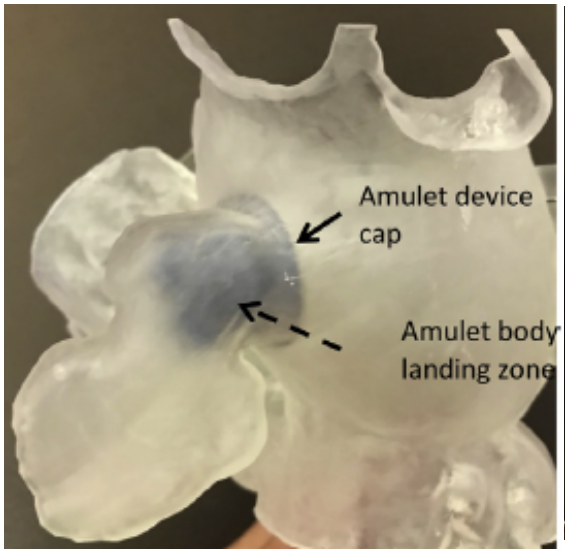

Korsholm, K. et al. J Am Coll Cardiol Intv. 2020;13(3):277-92.

FOLLOW-UP APRÈS OCCLUSION D'AG

- Position de la prothèse (embolisation ?)
- Occlusion complète ?
- Taux de compression de la prothèse
- Complications
  - Épanchement péricardique
  - Complication % ponction du SIA
  - Embolisation de la prothèse
  - Thrombus
  - Compression de la veine pulmonaire supérieure G ou de l'artère circonflexe

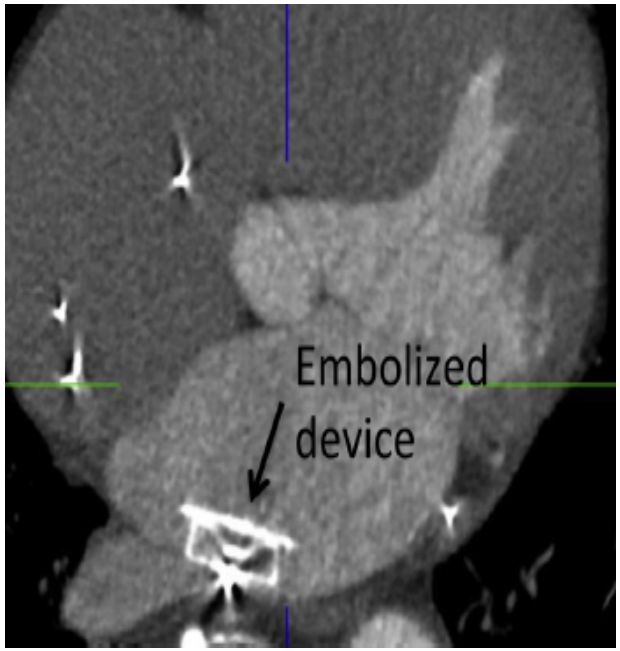

Saw J, Can J Cardiol 2016

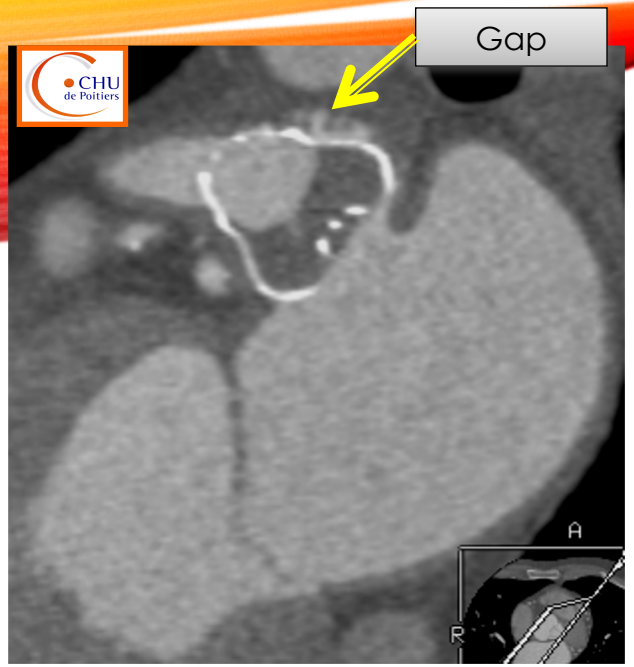

Watchman 27 mm (à J45)

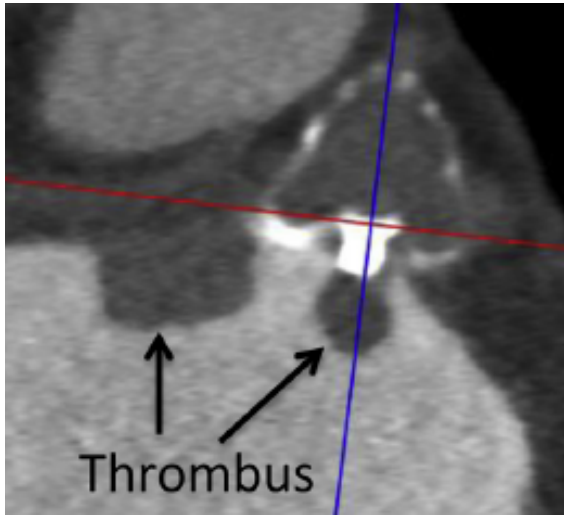

Saw J, Can J Cardiol 2016

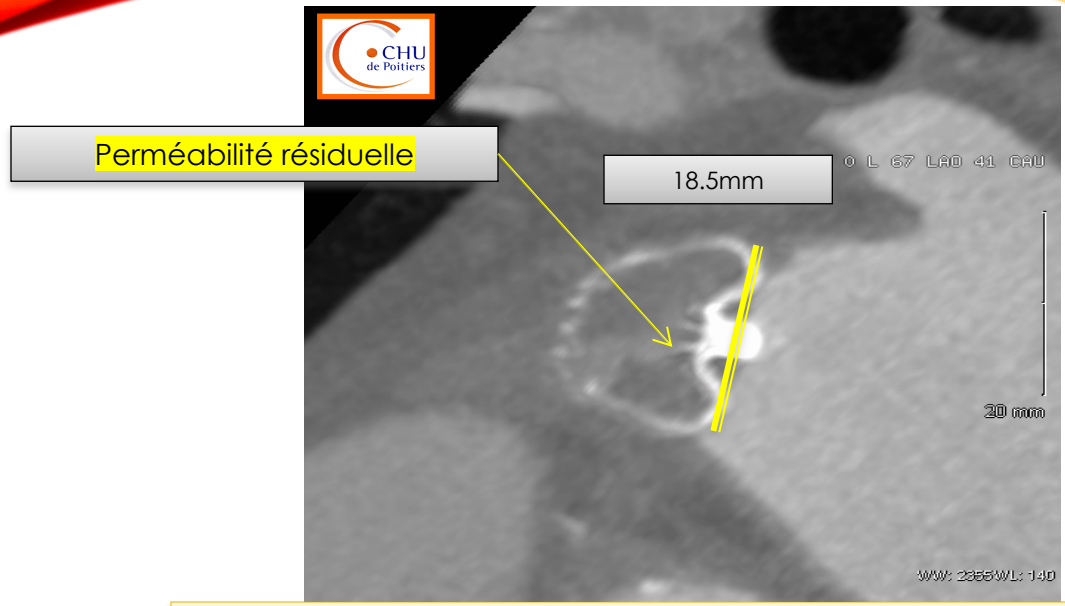

Watchman 21 mm (à J30) Compression 12-14%

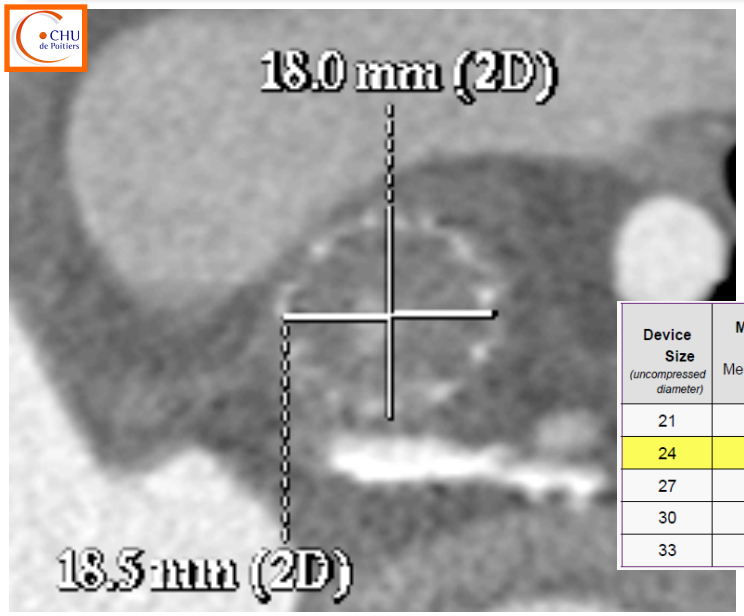

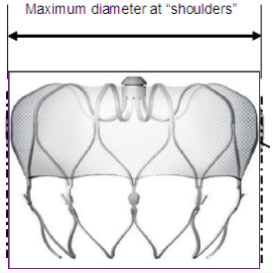

Device Size (uncompressed diameter)	Maximum (20%) Compression Measured Diameter*	Minimum (8%) Compression Measured Diameter*
21	16.8 mm	19.3 mm
24	19.2 mm	22.1 mm
27	21.6 mm	24.8 mm
30	24.0 mm	27.6 mm
33	26.4 mm	30.4 mm

Watchman (27 mm) à 6 mois

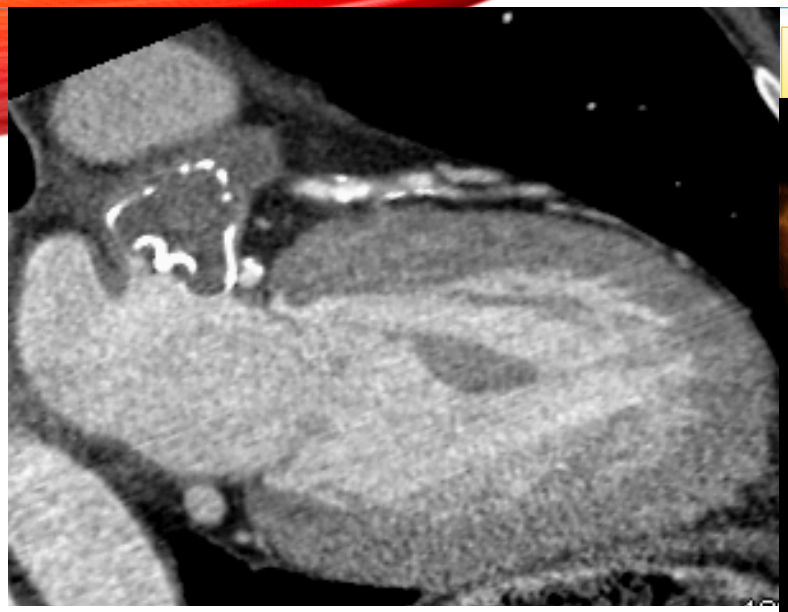

Watchman compression:
8% à 20% / diamètre de référence

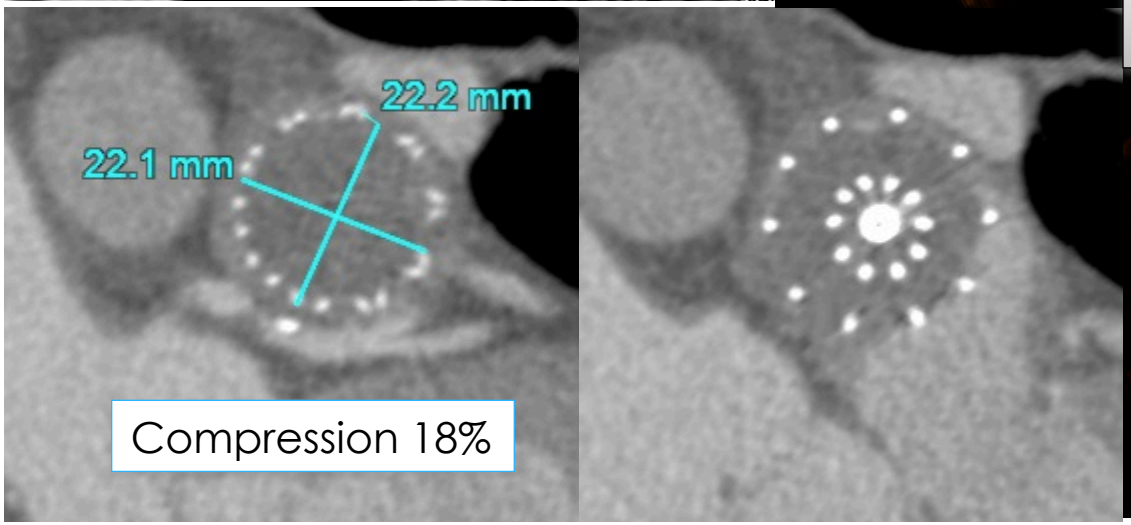

Radiology, CNR (National Counsil of Research)/ Tuscany Region "Gabriele Monasterio" Foundation, Heart Hospital - Massa (MS)/IT

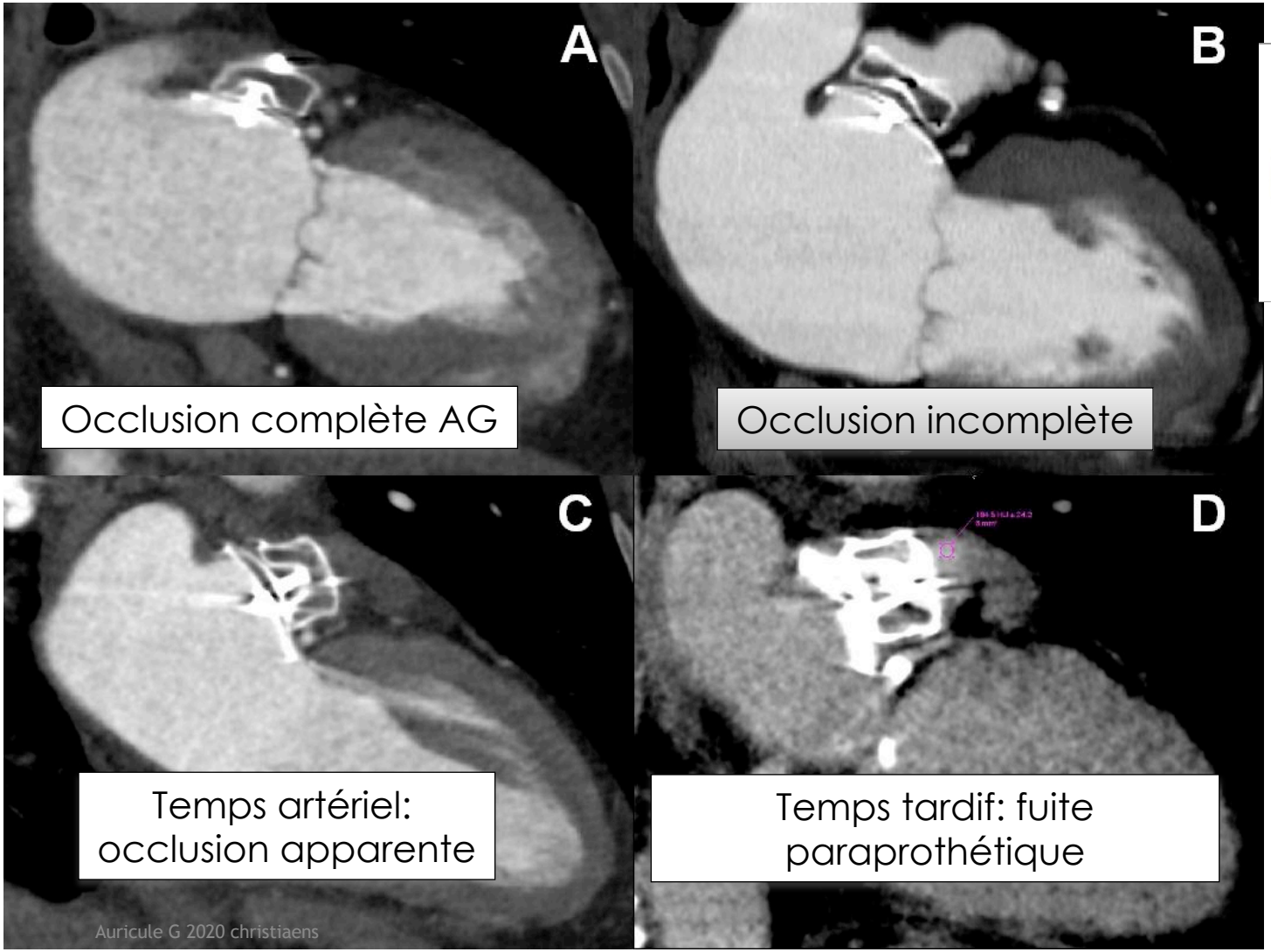

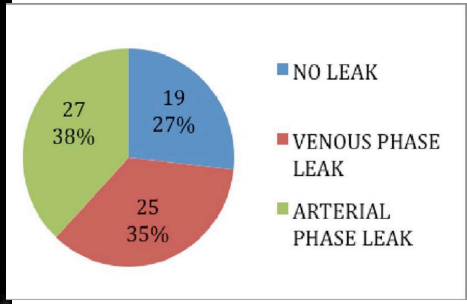

Radiology, CNR (National Counsil of Research)/ Tuscany Region "Gabriele Monasterio" Foundation, Heart Hospital - Massa (MS)/IT

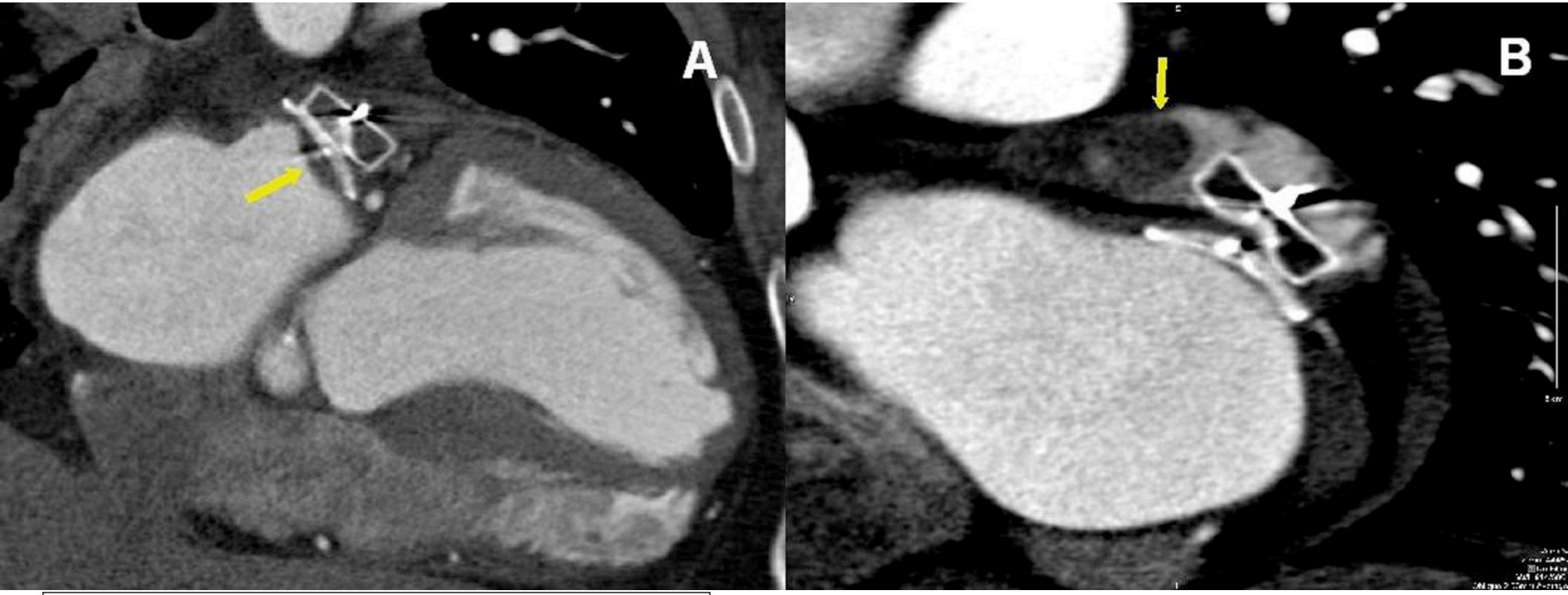

Thrombus accolé au disque de la prothèse

Thrombus au fond de l'AG

THROMBUS EXTENSIF SUR PROTHÈSE D'AURICULE GAUCHE

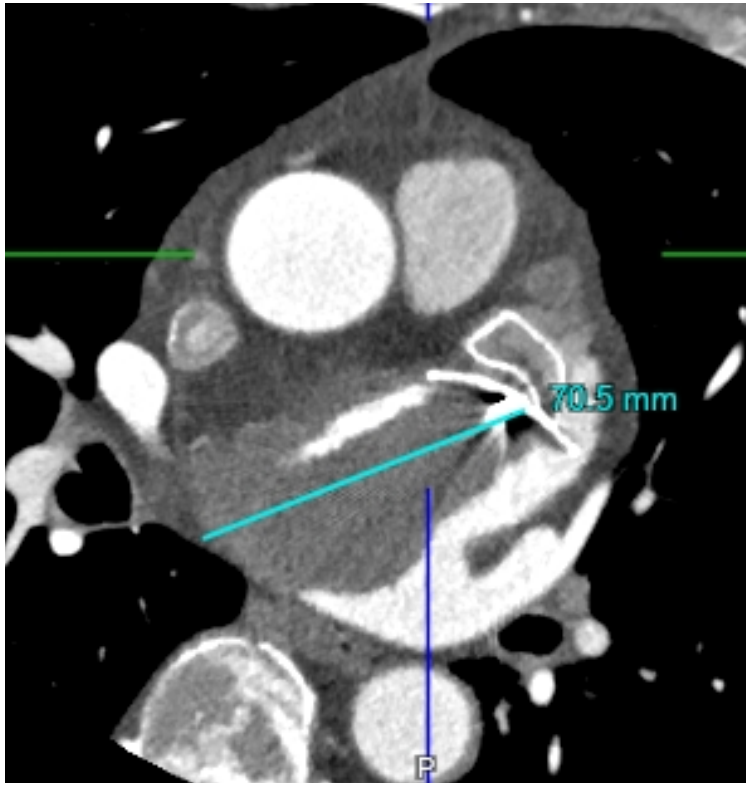

A RETENIR

- 4 morphologies types de l'auricule G
- Savoir rechercher un thrombus de l'auricule
- Savoir faire un sizing avant occlusion de l'auricule
- Savoir analyser un scanner après occlusion de l'auricule

RÉFÉRENCES

- Korsholm K, et al. Expert Recommendations on Cardiac Computed Tomography for Planning Transcatheter Left Atrial Appendage Occlusion. J Am Coll Cardiol Intv 2020;13:277–92
- Marom EM, et al. Radiology 2004;230:824-9
- Di Biase L, et al. Does the Left Atrial Appendage Morphology Correlate With the Risk of Stroke in Patients With Atrial Fibrillation? Results From a Multicenter Study. J Am Coll Cardiol 2012;60:531–8
- Ismail TF, et al. CT imaging for left atrial appendage closure: A review and pictorial essay. J Cardiovasc Computed Tomography 2015;9:89-102
- Kiuchi K, et al. Topographic variability of the left atrium and pulmonary veins assessed by3D-CT predicts the recurrence of atrial fibrillation after catheter ablation. Journal ofArrhythmia 2015;31:286–292