Les cardiopathies congénitales à l'âge adulte

Karine Warin-Fresse
Imagerie cardio-vasculaire
CHU Nantes

Epidémiologie

- 6 à 8 naissances vivantes sur 1000
- Survie à l'âge adulte: 85%
- Soit environ 2800 GUCH/ million d'habitants dans la population générale

- Suivi cardiologique spécialisé +++

Techniques d’imagerie

- Echocardiographie +++
- IRM
- Scanner

IRM

- Etude morphologique
  - Concordance auriculo-ventriculaire et ventriculo-artérielle
  - Montages chirurgicaux
  - Angio 3D des vaisseaux
- Etude fonctionnelle
  - SSFP: volumes ventriculaires / FE
  - Séquence en contraste de phase: fuites / sténoses
  - Qp/Qs
- Caractérisation tissulaire

IRM: étude morphologique

- Séquence Haste
- Séquence True fisp

IRM

- Etude morphologique
  - Concordance auriculo-ventriculaire et ventriculo-artérielle
  - Montages chirurgicaux
  - Angio 3D des vaisseaux
- Etude fonctionnelle
  - SSFP: volumes ventriculaires / FE / valves
  - Séquence en contraste de phase: fuites / sténoses
  - Qp/Qs
- Rehaussement tardif

Etude Fonctionnelle du VD

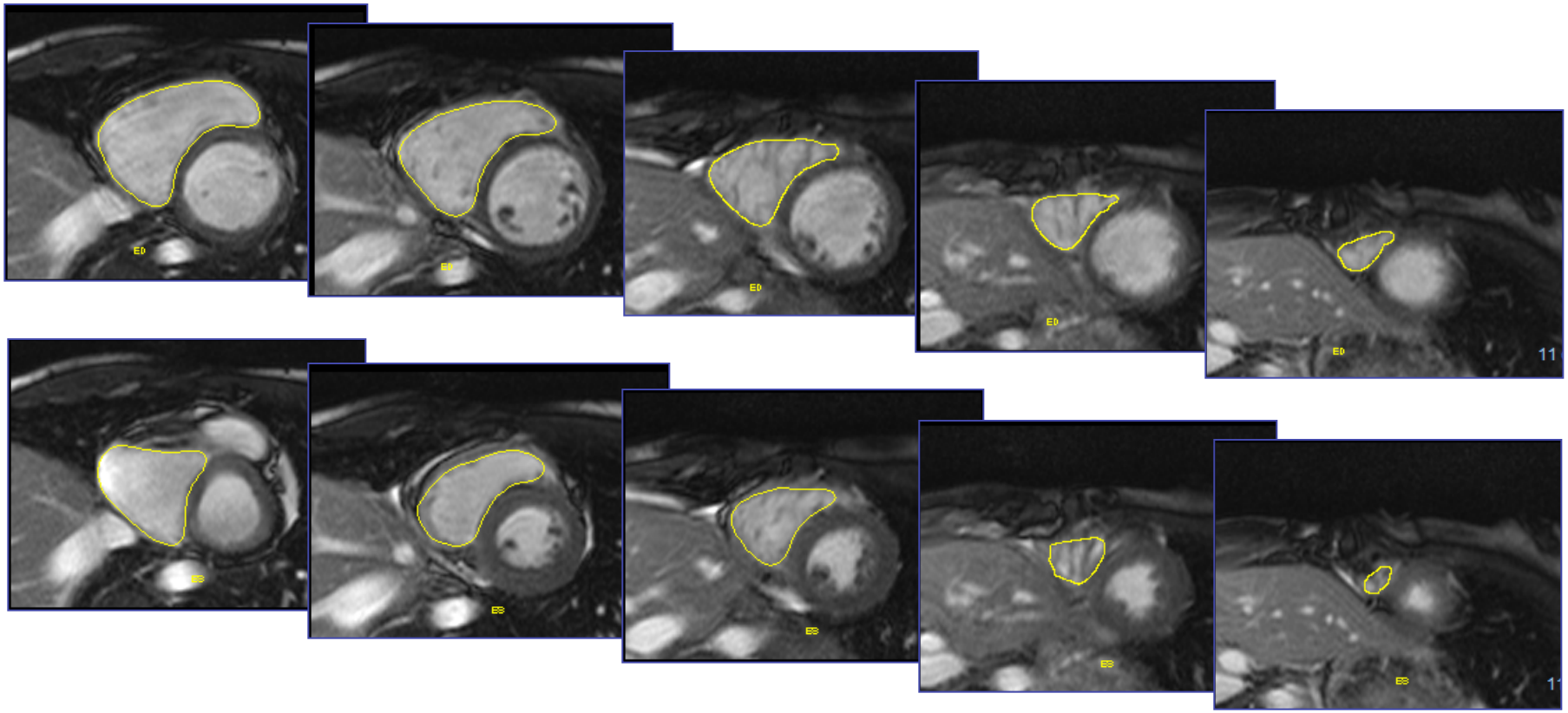

Patient Height: 180.00 cm. Patient Weight: 60.00 kg. Heart Rate: 65 Beats/min

Right Ventricle - Absolute

Cardiac Function			Normal Range (M) (MRI)	Units
Ejection Fraction	EF	51.5	47.00 ... 74.00	%
End Diastolic Volume	EDV	148.8	88.00 ... 227.00	ml
End Systolic Volume	ESV	72.2	23.00 ... 103.00	ml
Stroke Volume	SV	76.6	52.00 ... 138.00	ml
Cardiac Output	CO	4.98	2.82 ... 8.82	l/min

Patient Height: 180.00 cm. Patient Weight: 60.00 kg. Heart Rate: 65 Beats/min

Right Ventricle - Normalized

Cardiac Function			Normal Range (M) (MRI)	Units
End Diastolic Volume	EDV	84.2	55.00 ... 105.00	ml/m^2
End Systolic Volume	ESV	40.9	15.43 ... 42.91	ml/m^2
Stroke Volume	SV	43.4	32.00 ... 64.00	ml/m^2
Cardiac Index	CI	2.82	1.74 ... 4.20	l/min/m^2
Myocardial Mass (at ED)		----	----	g/m^2

Etude Fonctionnelle du VD

- **Séquence de flux en contraste de phase**
  - Encodage de phase du signal IRM
  - Proportionnel à la vitesse de déplacement des spins
  - Selon une direction donnée perpendiculaire au plan de coupe
- Q(ml/cycle) = Vmoy X Svx
- $\Delta P = 4 \times V^2 max$

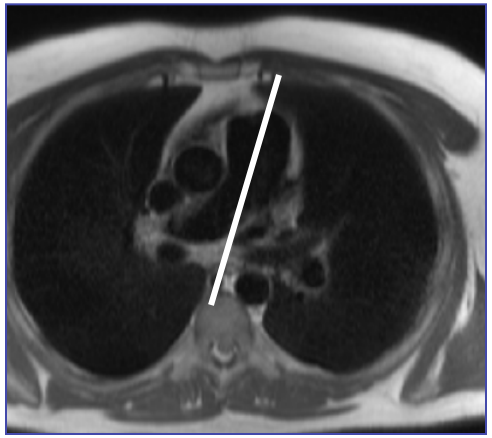

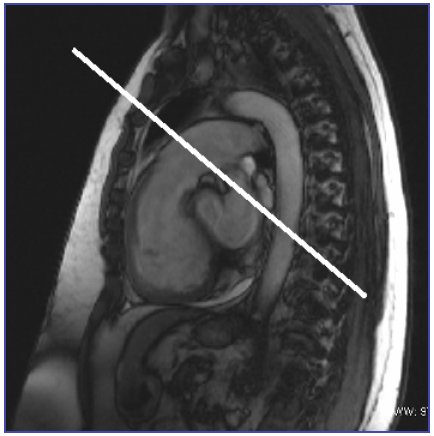

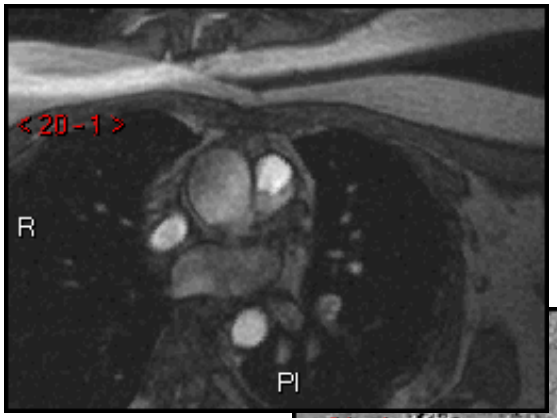

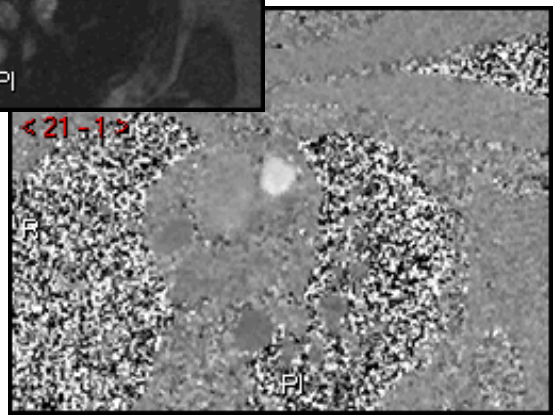

Scanner

- Morphologie
  - Très bonne résolution spatiale
  - Temps d'exploration court
  - Coronaires +++

- Fonction
  - Quand synchronisé à l'ECG: volumes ventriculaires / fonction / valve
  - Mais irradiant +++

scanner

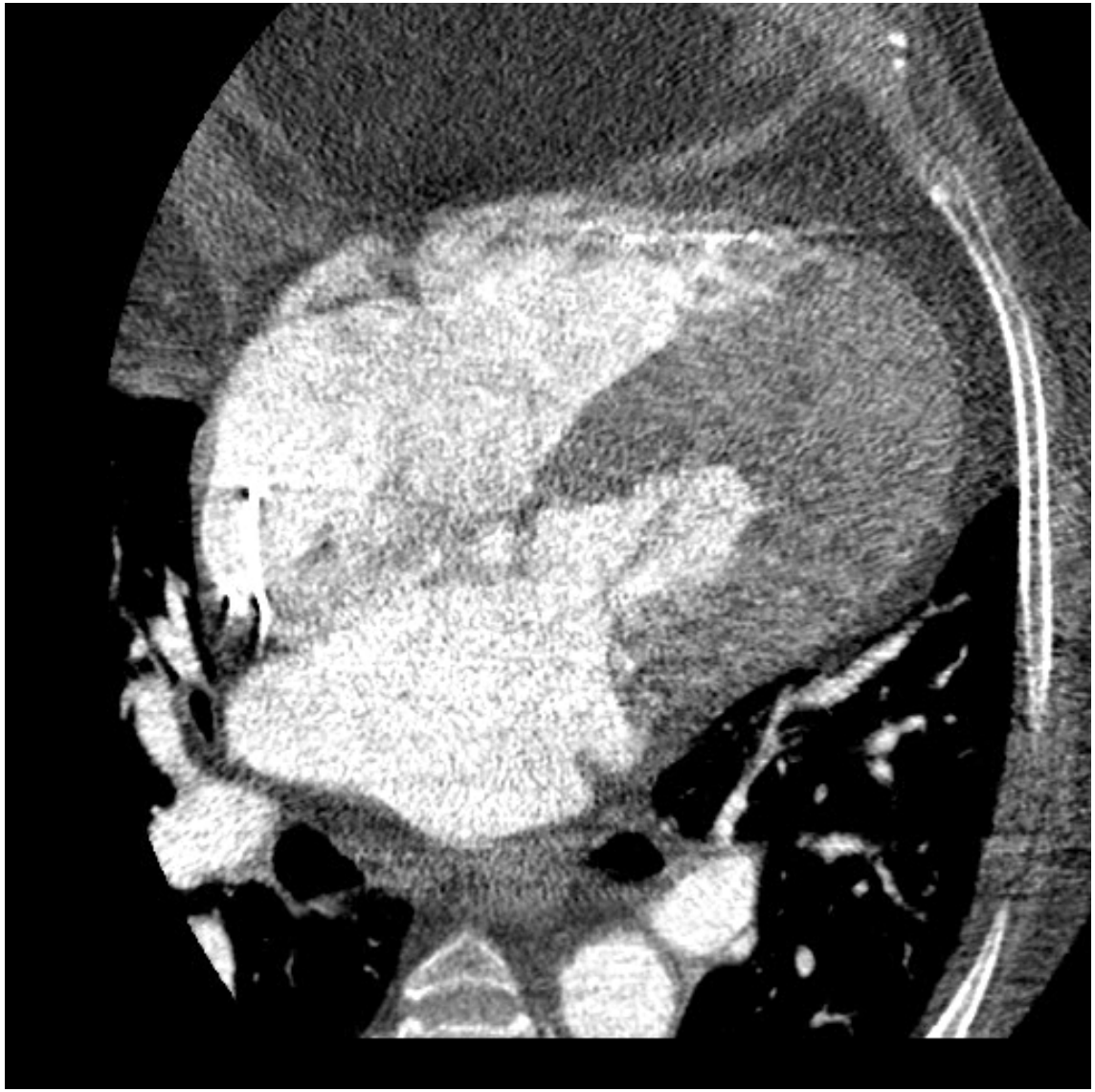

Cardiopathies congénitales

- Tétralogie de Fallot
- Atrésies pulmonaires
- Transposition des gros vaisseaux
- Double discordance
- Maladie d'Ebstein

- Anomalie vasculaires
  - Coarctation
  - Anomalies des arcs aortiques
- Anomalies coronaires

Cardiopathies congénitales

- **Tétralogie de Fallot**
- Atrésies pulmonaires
- Transposition des gros vaisseaux
- Double discordance
- Maladie d’Ebstein
- Ventricule unique

TOF: épidémiologie

- 10% des CP congénitales en période néonatale
- Incidence: 0,4 à 0,8 naissances / 1000
- Prévalence 45 / 100 000

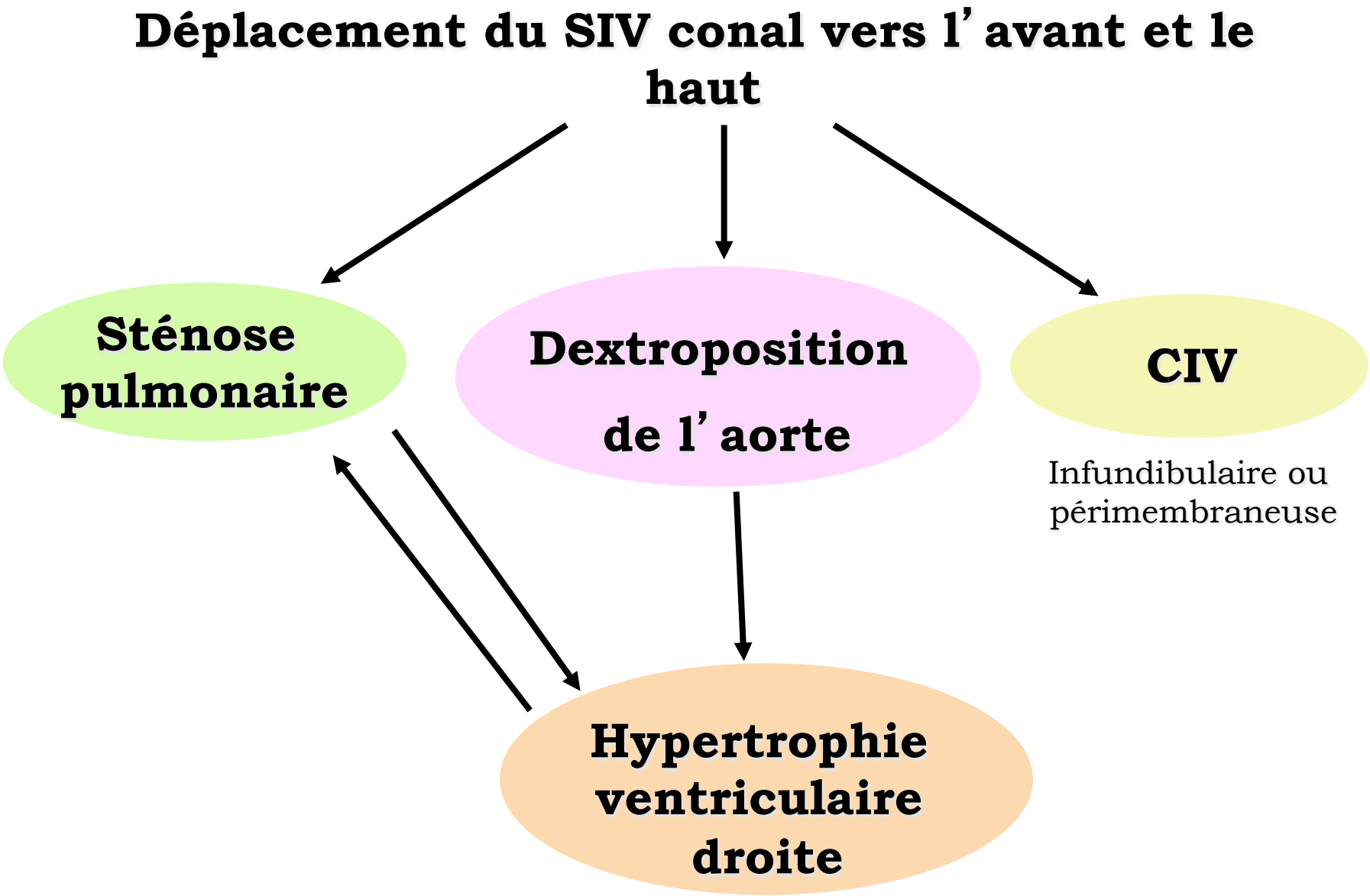

=> Shunt droite - gauche: CP cyanogène

Tétralogie de Fallot

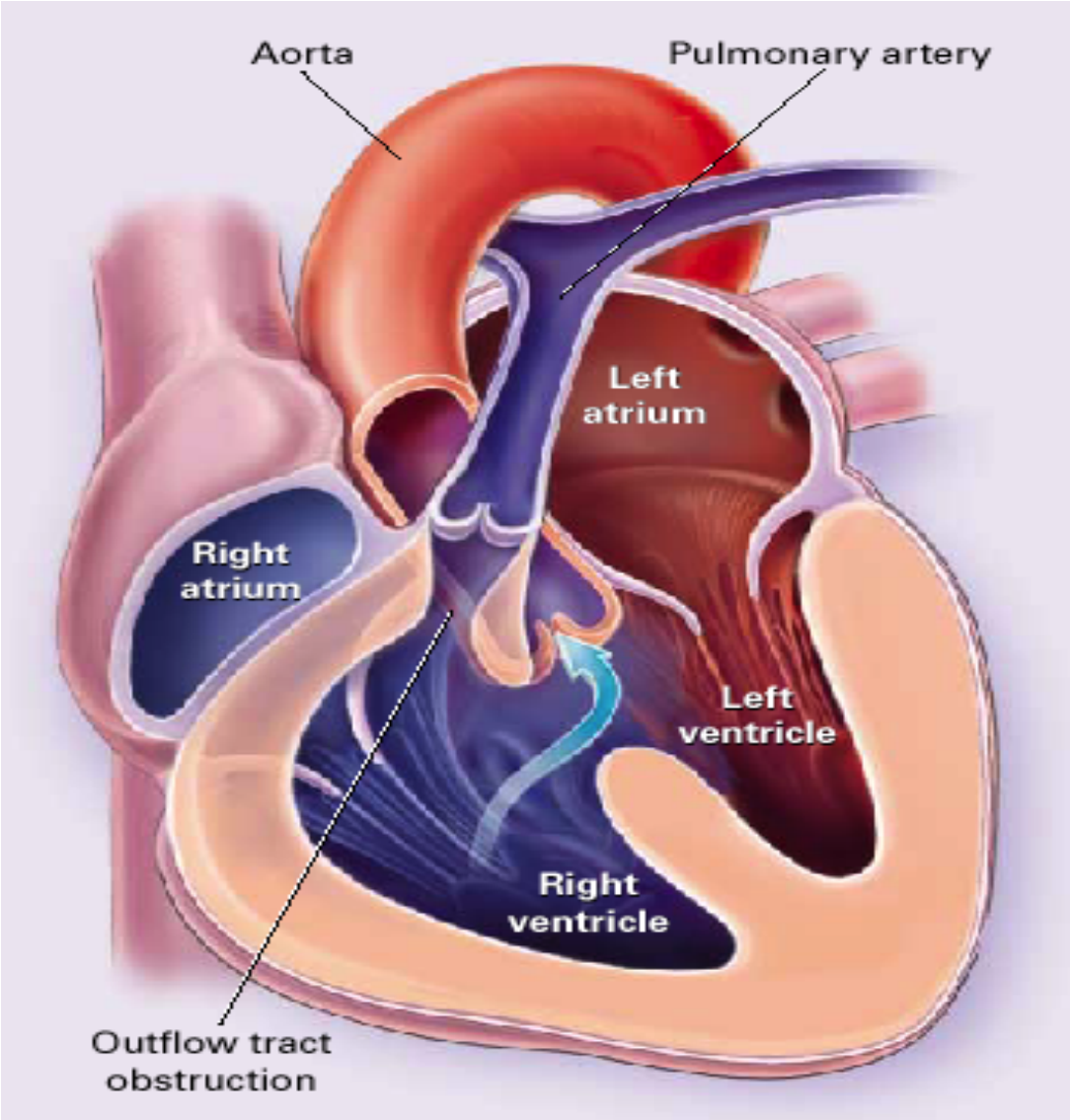

TOF: conséquences de la chirurgie

- Fuite pulmonaire
- Dilatation VD
- Altération de la FEVD
- Troubles du rythme

< 20 - 1 >
AL
I
Patient Height: 160.00 cm. Patient Weight: 63.00 kg. Heart Rate: 81 Beats/min
Flow vs Time
ml/sec
Legend:
Data
Spline (+/- 1)
438
338
238
138
38
-62
-162
-262
-362
-462
-562
0
60
120
180
240
300
360
420
480
540
600
Time (ms)
Slice Position: SP L35.9 Venc Adjustment -500 : 500
Check contours. Computer generated contours may not correspond to anatomy.

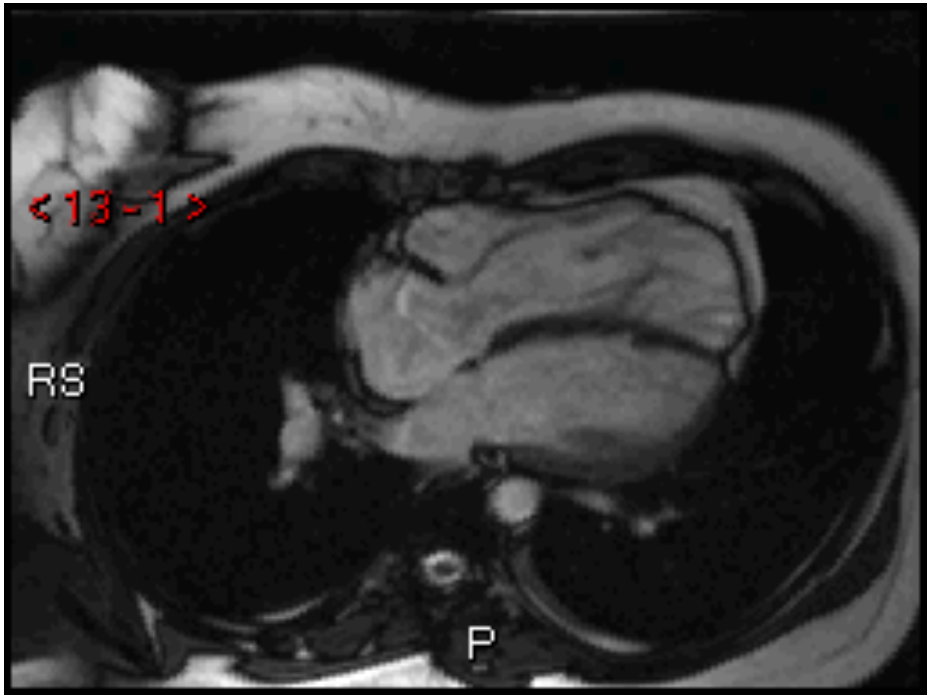

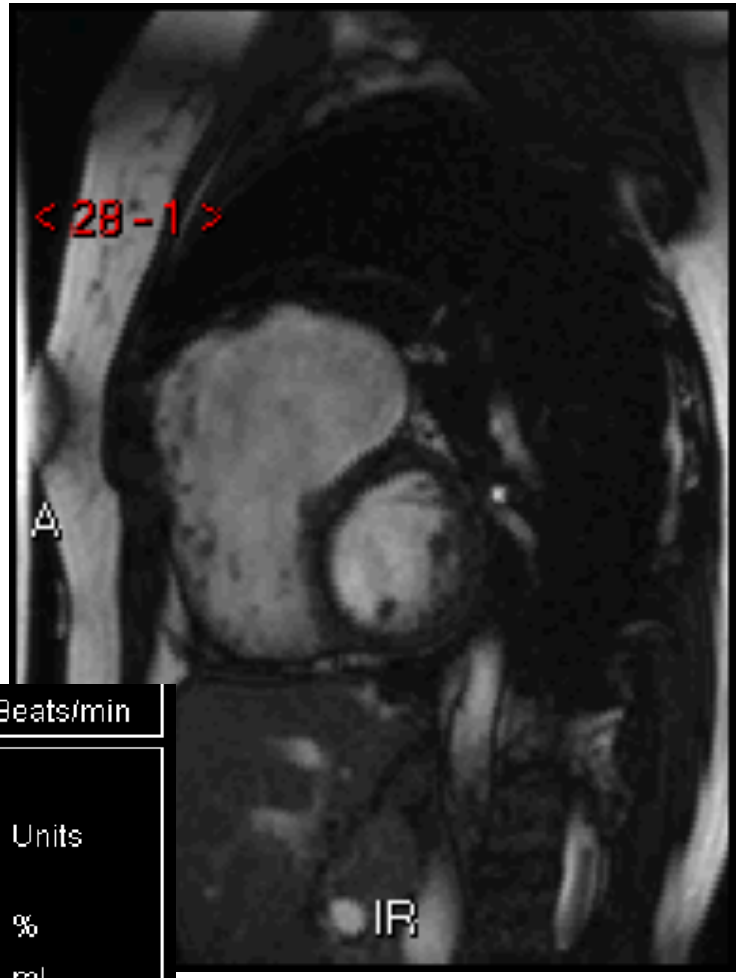

Patient Height: 160.00 cm. Patient Weight: 63.00 kg. Heart Rate: 80 Beats/min

Right Ventricle - Absolute

Cardiac Function			Normal Range (F) (MRI)	Units
Ejection Fraction	EF	31.5	47.00 ... 80.00	%
End Diastolic Volume	EDV	386.8	58.00 ... 154.00	ml
End Systolic Volume	ESV	264.9	12.00 ... 68.00	ml
Stroke Volume	SV	122.0	35.00 ... 98.00	ml
Cardiac Output	CO	9.76	2.65 ... 5.98	l/min
End Diastolic Volume	EDV	233.6	48.00 ... 87.00	ml/m^2
End Systolic Volume	ESV	159.9	11.01 ... 27.60	ml/m^2
Stroke Volume	SV	73.7	27.00 ... 57.00	ml/m^2
Cardiac Index	CI	5.89	1.75 ... 3.80	l/min/m^2

Pourquoi?

Khairy P, Dore A, Poirier N, et al. (2009) Risk stratification in surgically repaired tetralogy
of Fallot. Expert Rev Cardiovasc Ther 7: 755-62
11. Khairy P, Aboulhosn J, Gurvitz MZ, et al. (2010) Arrhythmia burden in adults with
surgically repaired tetralogy of Fallot: a multi-institutional study. Circulation 122: 868-75

TOF: Revalvulation pulmonaire

Indiquée quand le VTDVD > **150-170 ml/m²**

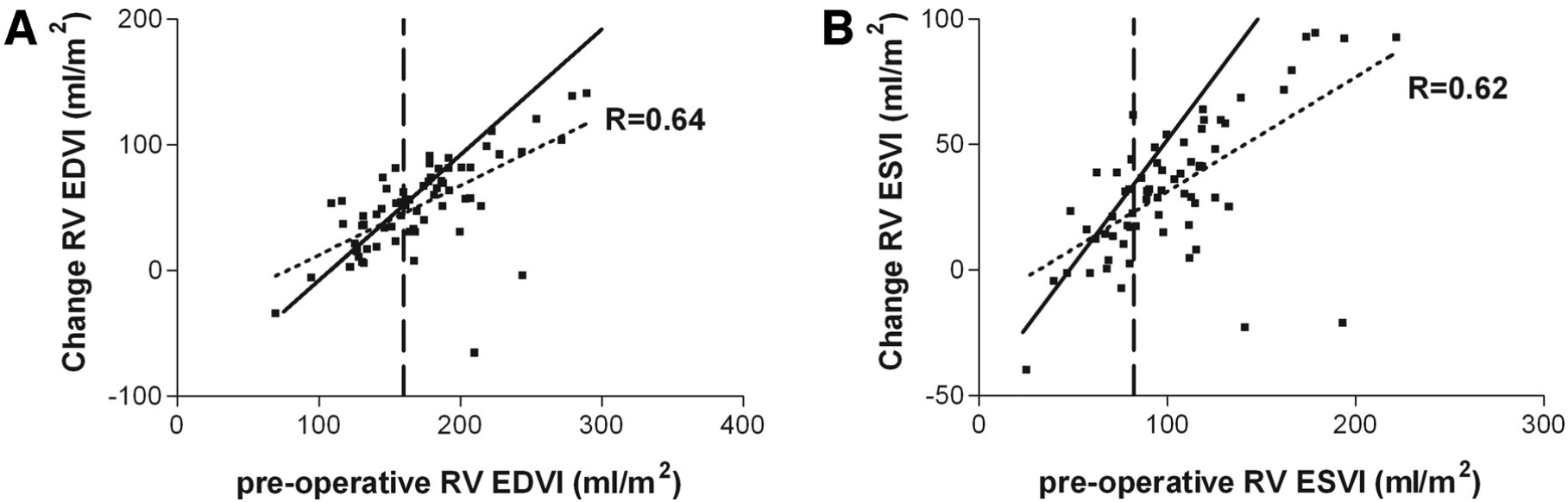

Figure 3. The association with preoperative RV EDVI (A) or RV ESVI (B) and the absolute decrease in RV volumes after surgery is depicted (dashed line is the regression line).

Oosterhof T *et al*. Circulation 2007;116:545-551

TABLE 3. Relationship of Documented Clinical Arrhythmia After Repaired TOF to Symptoms, Exercise Capacity, and RV LGE Score

	No Arrhythmia (n=76)	Arrhythmia* (n=16)	*P*
Age, y†	31.2±10.6	36.9±12.3	0.043
New York Heart Association class ≥2	12/76	8/16	0.006
Redo surgery, n (%)	8/76 (11)	8/16 (50)	0.004
Peak heart rate, bpm	171 (162–186)	151 (114–171)	0.07
Exercise duration, s†	781±22	622±194	0.002
Maximum $\dot{V}O_2$, $mL \cdot min^{-1} \cdot kg^{-1}$	27.1±7.6	23.4±4.4	0.079
QRS duration, ms	158 (148–167)	155 (143–164)	NS
QRS dispersion, ms	41±11	40±5	NS
QT dispersion, ms	85±30	78±32	NS
JT dispersion, ms	80±30	73±28	NS
Anterior RV LGE‡	19/76	9/16	0.017
RV LGE score†	3.0 (3.0–5.0)	5.5 (3.8–12.0)	0.032
Non–apical vent LV LGE	7/76	5/16	0.017

*Please see footnote (§) in Table 1.
†Clinically important variables entered into multivariate model.
‡Anterior RV LGE refers to the free wall of the RV below the RVOT.

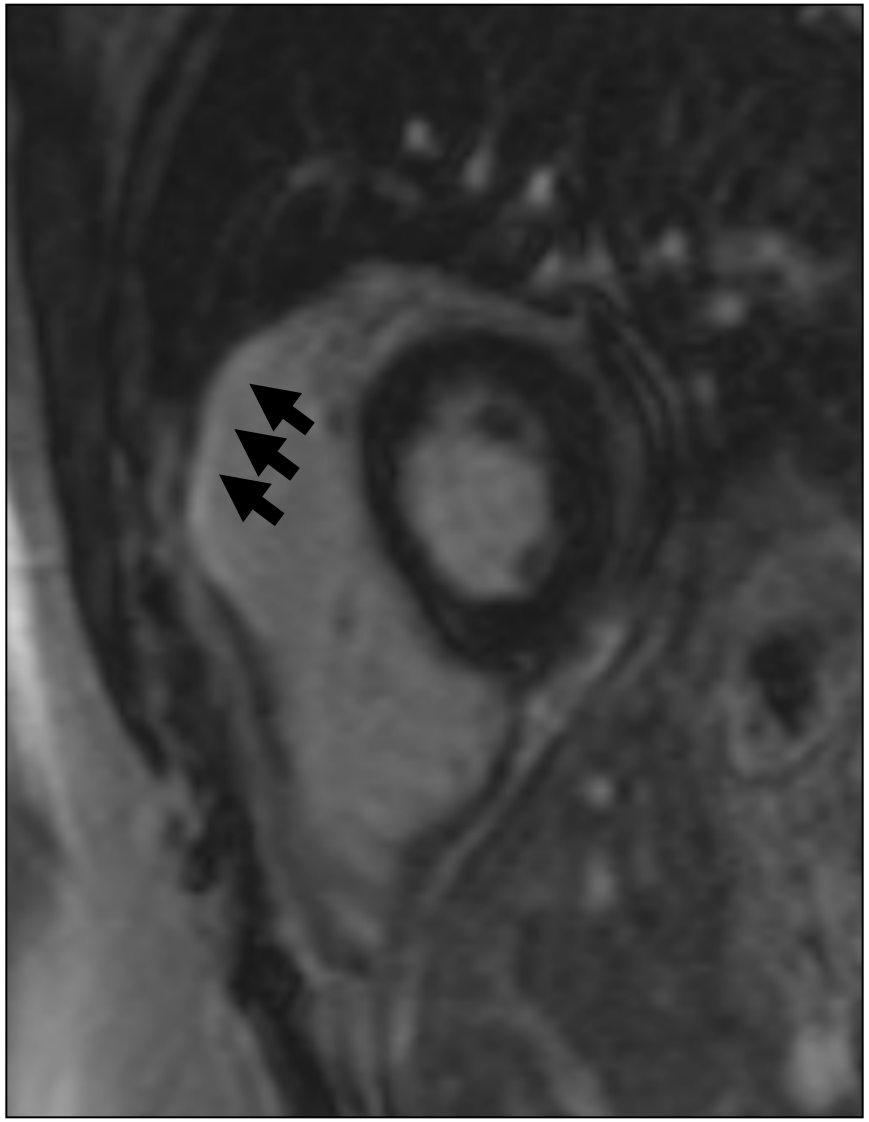

Babu-Narayan SV, Kilner PJ, Li W, *et al.* 2006 Circulation 113: 405-13

Aorte dans la TOF

- Khairy P, circulation 2013:

- n = 474
- Ao > 40 mm: 137 (28,9%)
- Ao < 40 mm: 437

- The only factor independently associated with an aortic root diameter ≥40 mm was male sex (odds ratio, 4.48; 95% CI, 1.55–12.89; *P*=0.006)

- only 3 cases of aortic dissection have been reported in patients with TOF thus far, rendering it an exceedingly rare complication

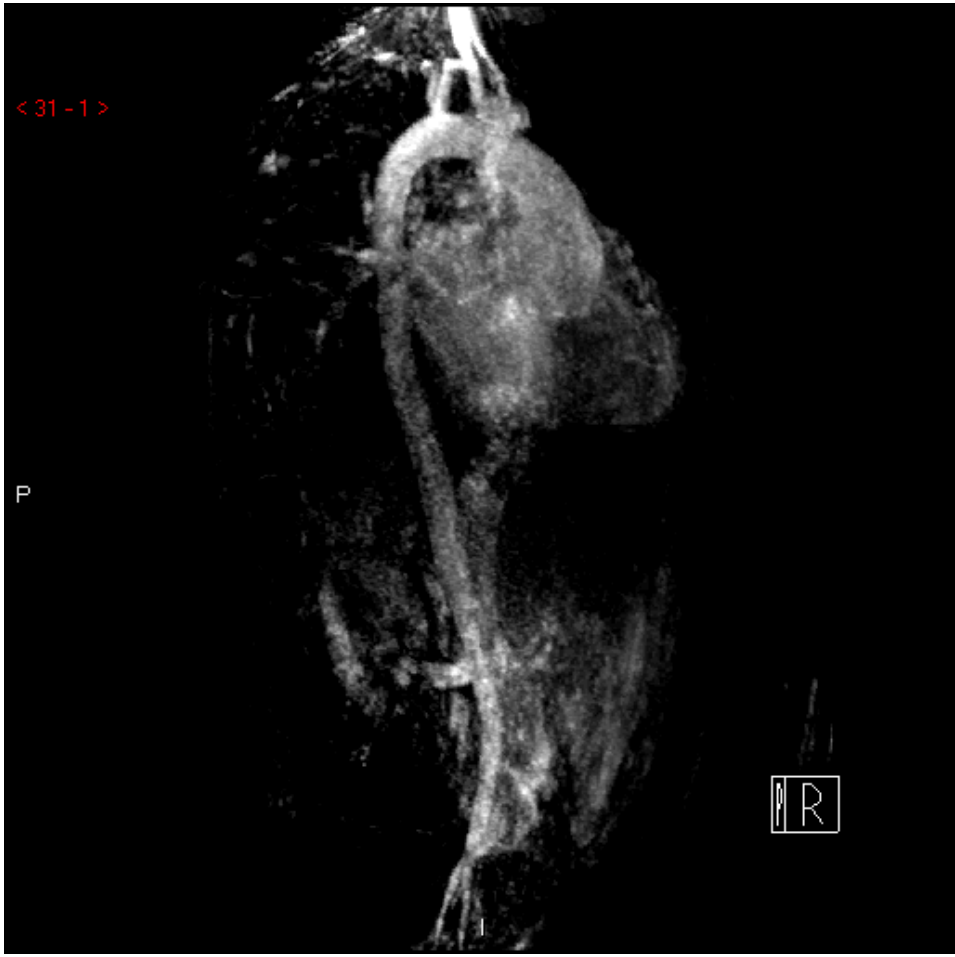

Artères pulmonaires dans la TOF

TOF: IRM

- Ventricule gauche

- Aorte

- Tan JL, Gatzoulis MA, Ho SY (2006) Aortic root disease in tetralogy of Fallot. Curr Opin Cardiol 21: 569-72
- Niwa K, Siu SC, Webb GD, Gatzoulis MA (2002) Progressive aortic root dilatation in adults late after repair of tetralogy of Fallot. Circulation 106: 1374-8

Cardiopathies congénitales

- Tétralogie de Fallot
- **Atrésies pulmonaires**
- Transposition des gros vaisseaux
- Double discordance
- Maladie d’Ebstein
- Ventricule unique

Atrésie pulmonaire

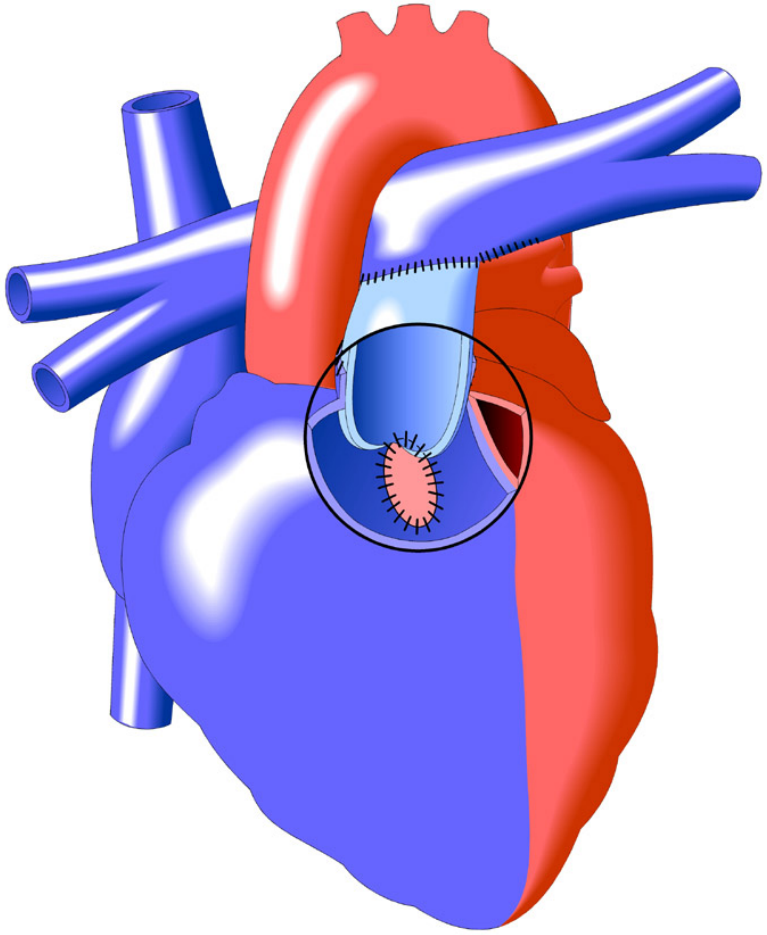

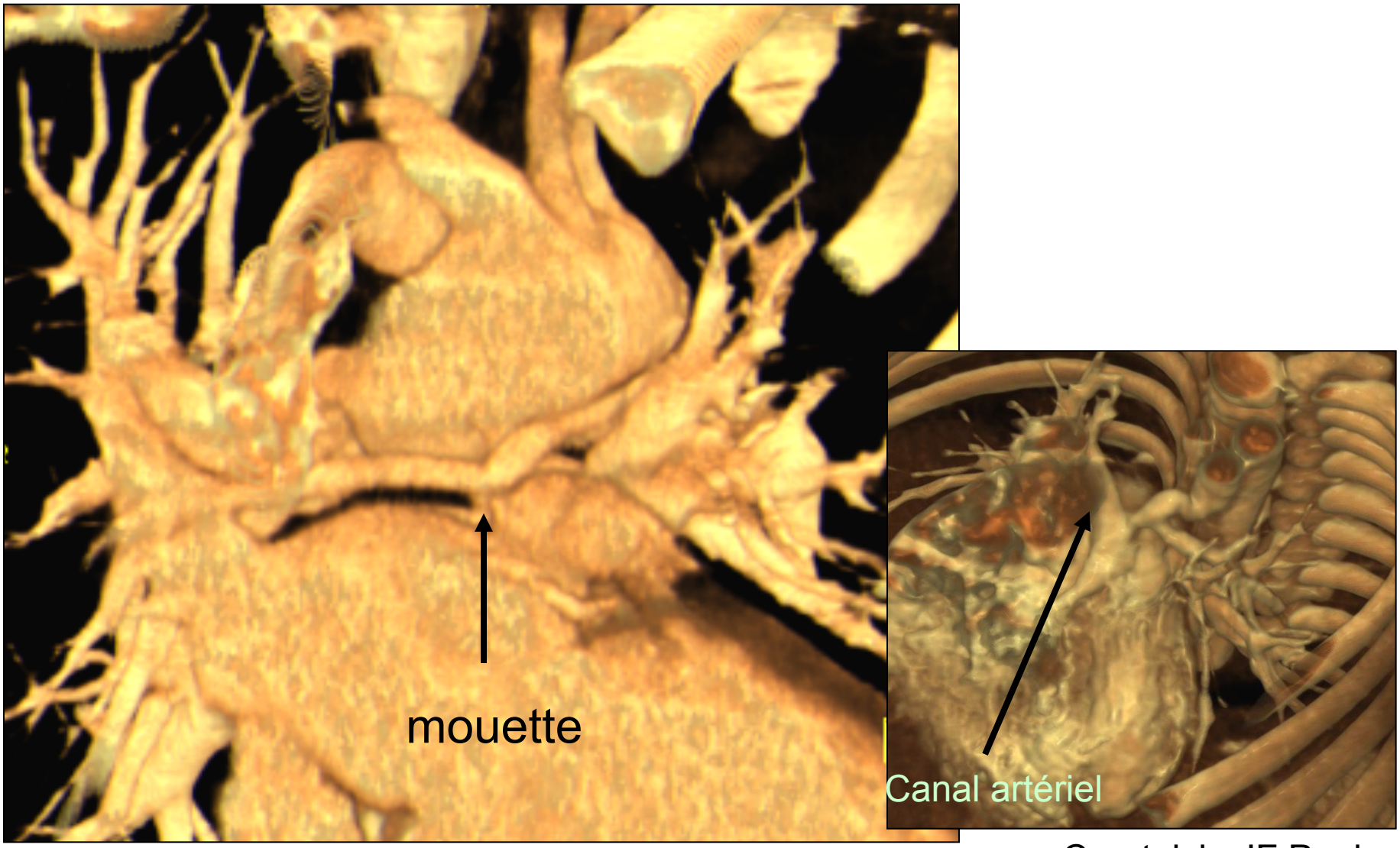

Courtoisie JF Paul

Tube VD AP

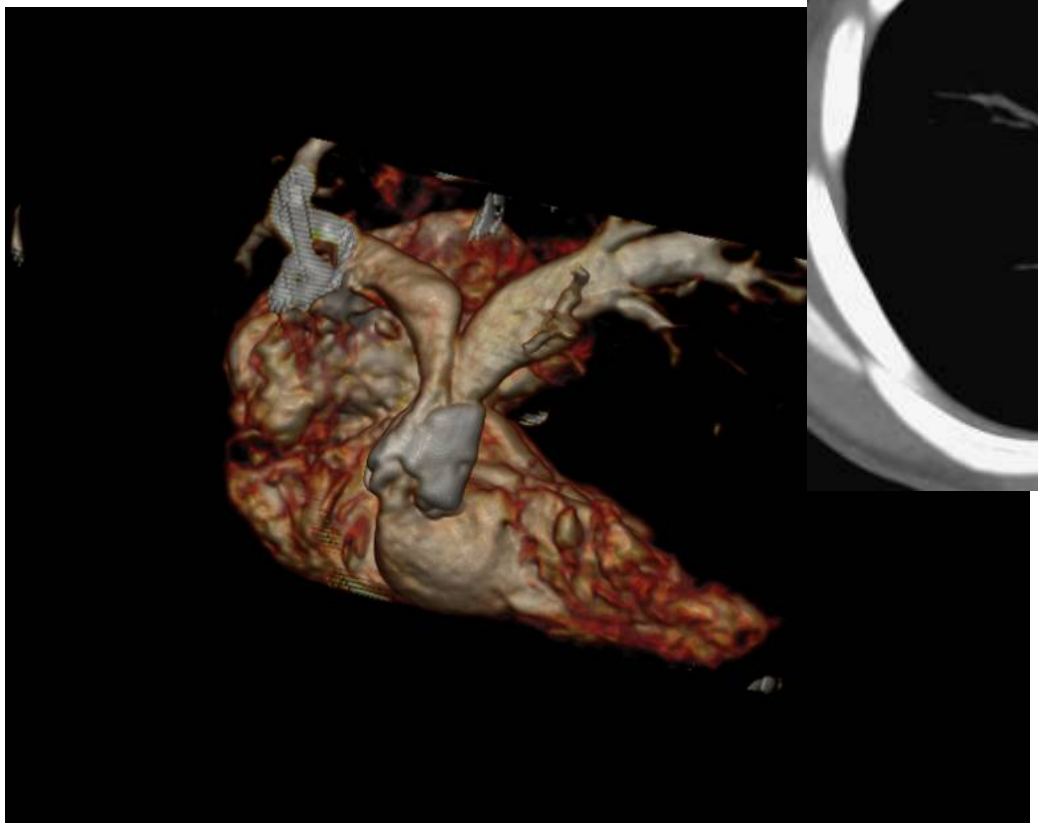

Unifocalisation

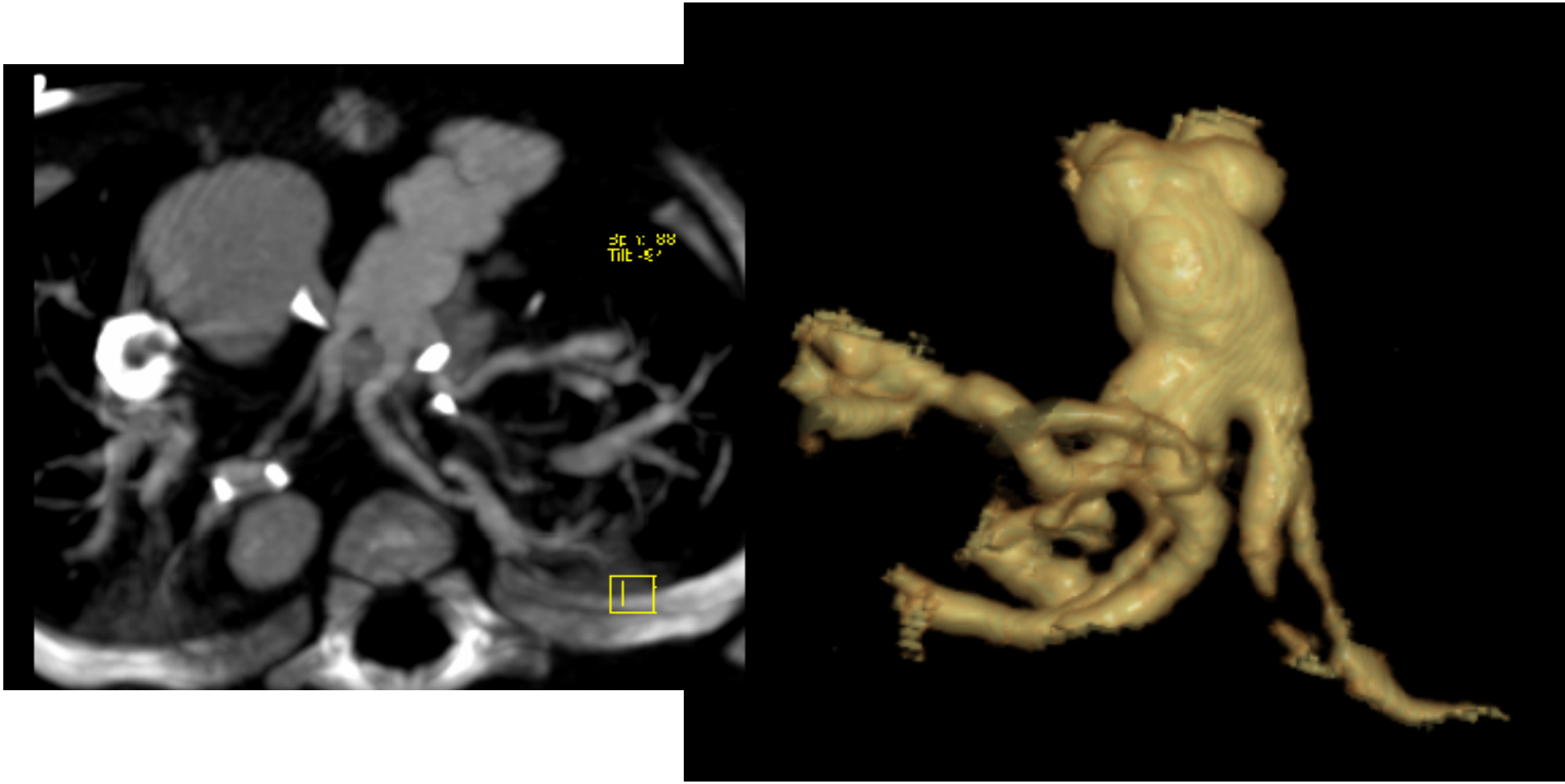

Réimplantation de collatérales aortiques dans un tube VD-AP

Cardiopathies congénitales

- Tétralogie de Fallot
- Atrésies pulmonaires
- **Transposition des gros vaisseaux**
- Double discordance
- Maladie d’Ebstein
- Ventricule unique

Cardiopathies congénitales

- Tétralogie de Fallot
- Atrésies pulmonaires
- **Transposition des gros vaisseaux**
- Double discordance
- Maladie d’Ebstein
- Ventricule unique

TGV: épidémiologie

- 5 % des cardiopathies congénitales
- Concordance auriculo- ventriculaire
- Et discordance ventriculo-artérielle

- Autres anomalies intracardiaques associées :
  - défaut interventriculaire (45 %),
  - obstruction sur la voie gauche (25 %)
  - coarctation (5 %)

1
2
3
OD
OG
VD
VG

< 23 - 1 >
A
I

TGV: réparation chirurgicale

- Dé-transposition à l’étage atrial: switch atrial
- Dé-transposition à l’étage artériel: switch artériel +++

TGV: switch atrial

- Mustard/Senning Repair -

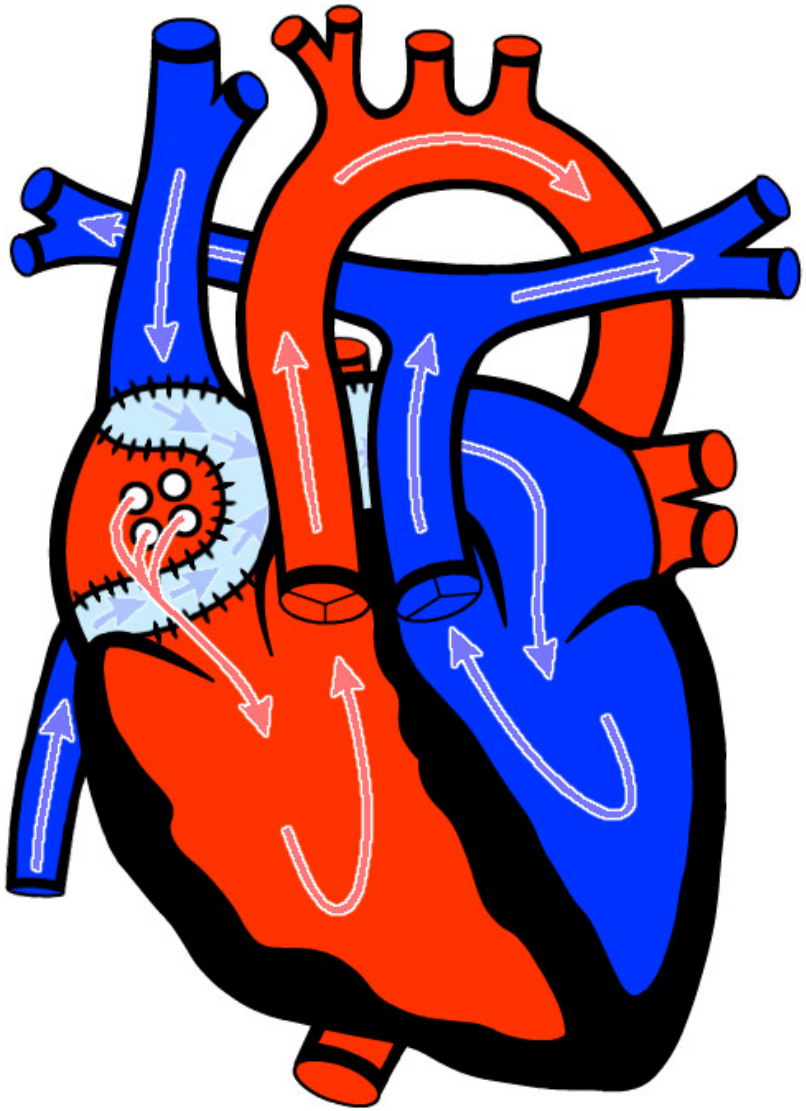

TGV: switch atrial

- Sténose des chenaux caves supérieur et / ou inférieur
- Sténose du collecteur des veines pulmonaires

- Dysfonction du ventricule droit sous aortique en position systémique
- Fuite tricuspide en position systémique

Sténose cave inférieure

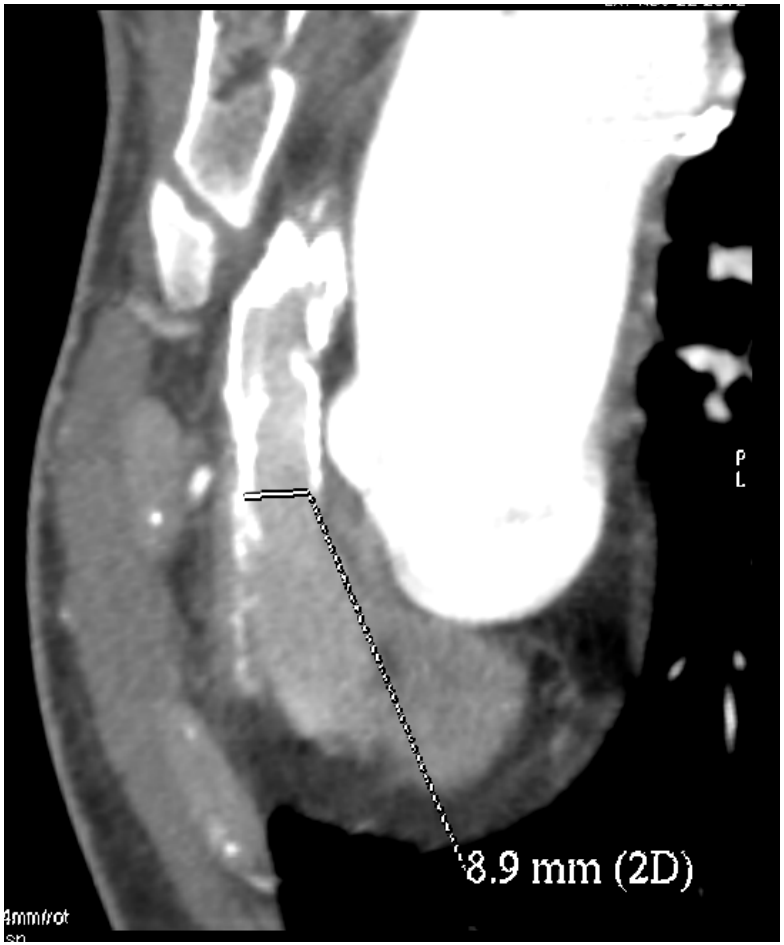

VD systémique sous aortique

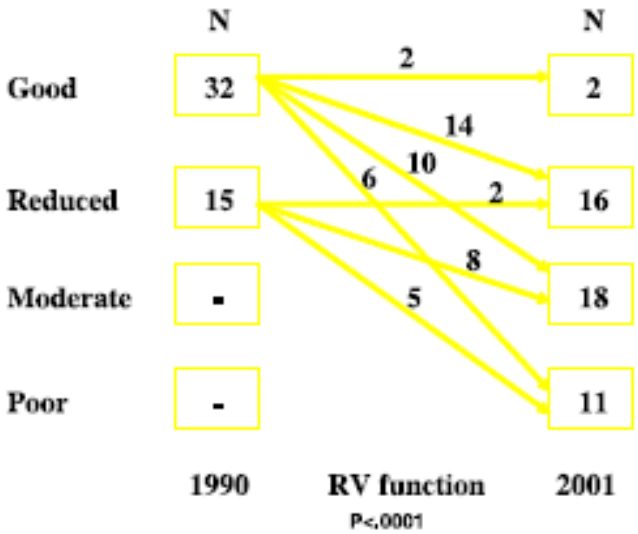

Fig. 5 Decline in systemic ventricular function between 1990 and 2001 measured with echocardiography.

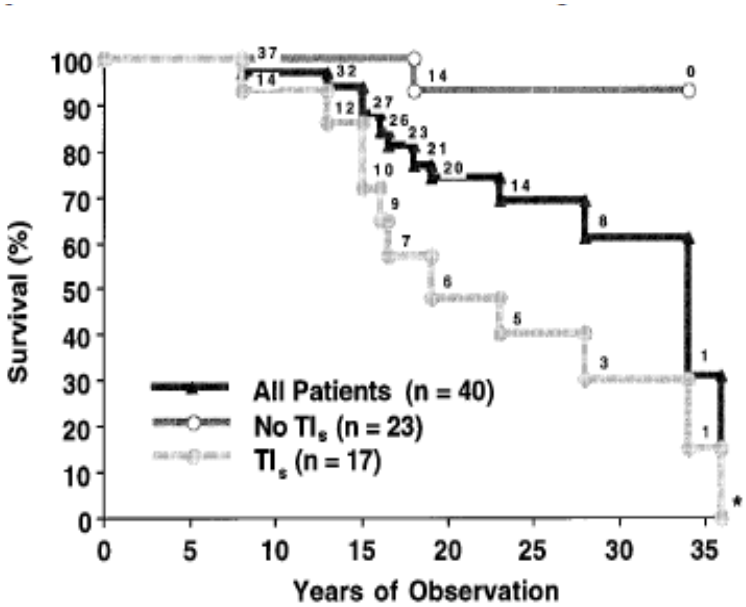

Ross-hesselink JW, Meijboom FJ *et al.* 2004 Eur Heart J 25: 1264-70

Prieto LR *et al.* 1998 Circulation 98: 997-1005

Survie après switch atrial

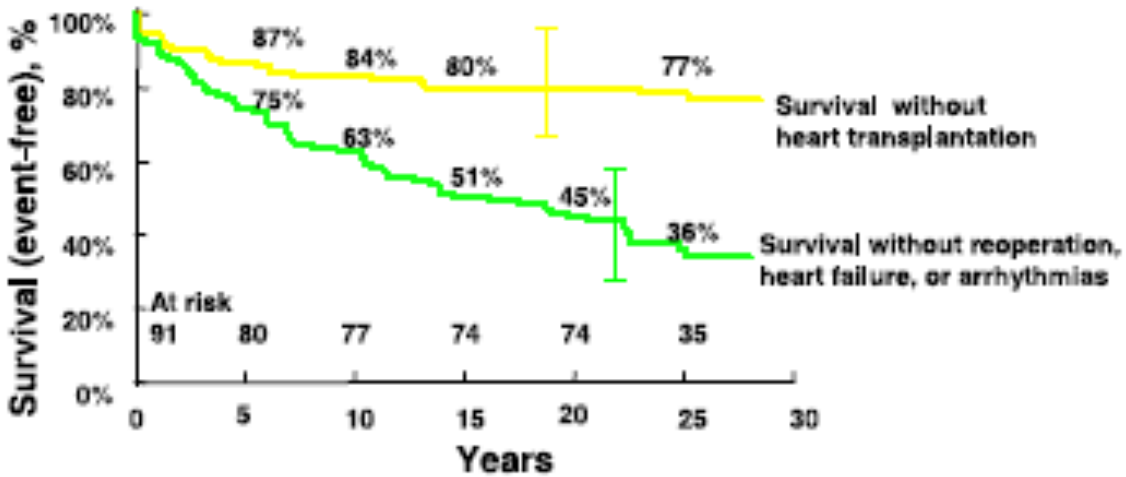

Fig. 1 Survival (event-free) after Mustard operation. Crossbars mark the 95% confidence intervals.

Ross-hesselink JW, Meijboom FJ *et al.* 2004 Eur Heart J 25: 1264-70

TGV: switch artériel

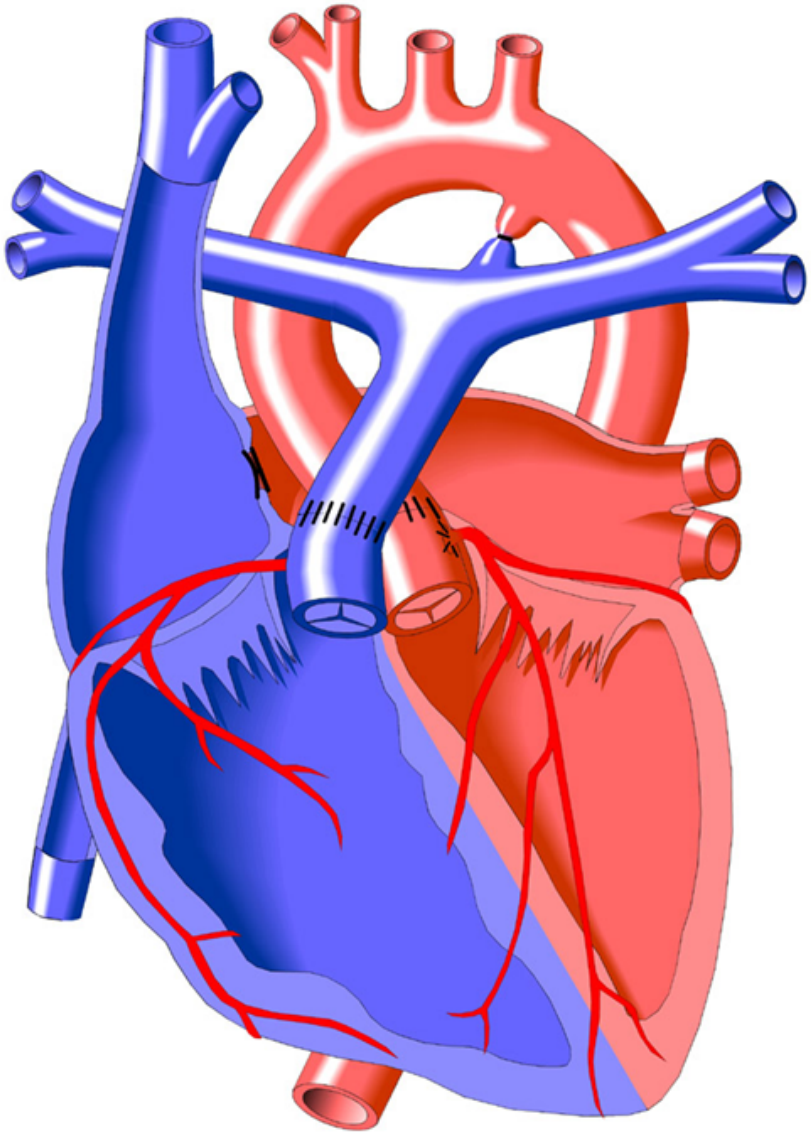

TGV: switch artériel

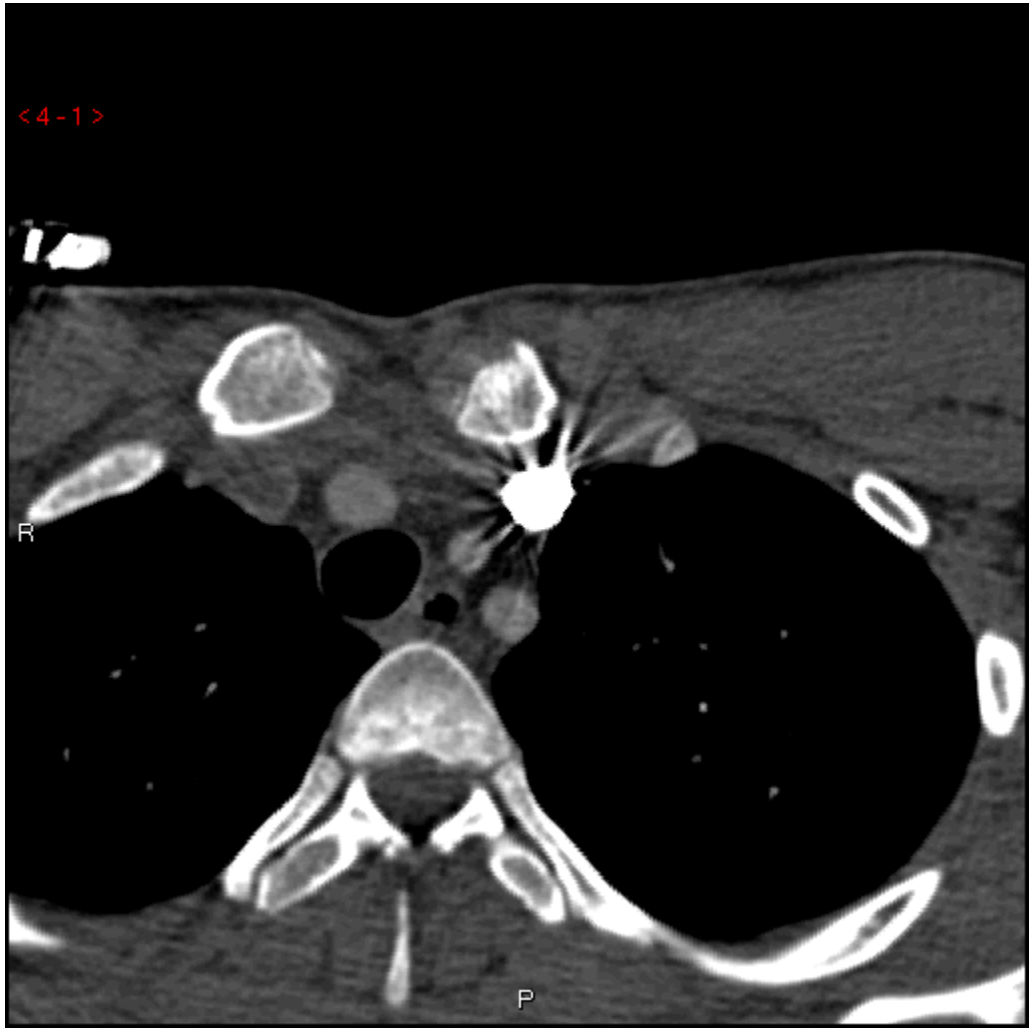

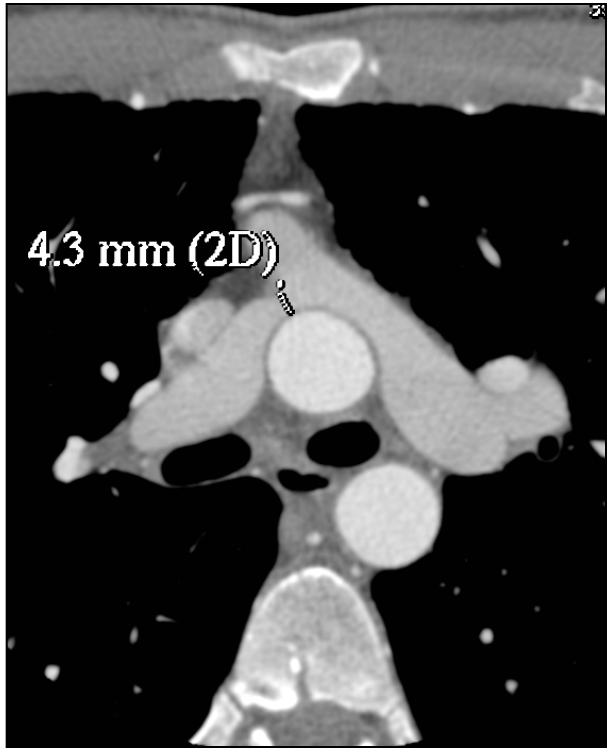
4.3 mm (2D)

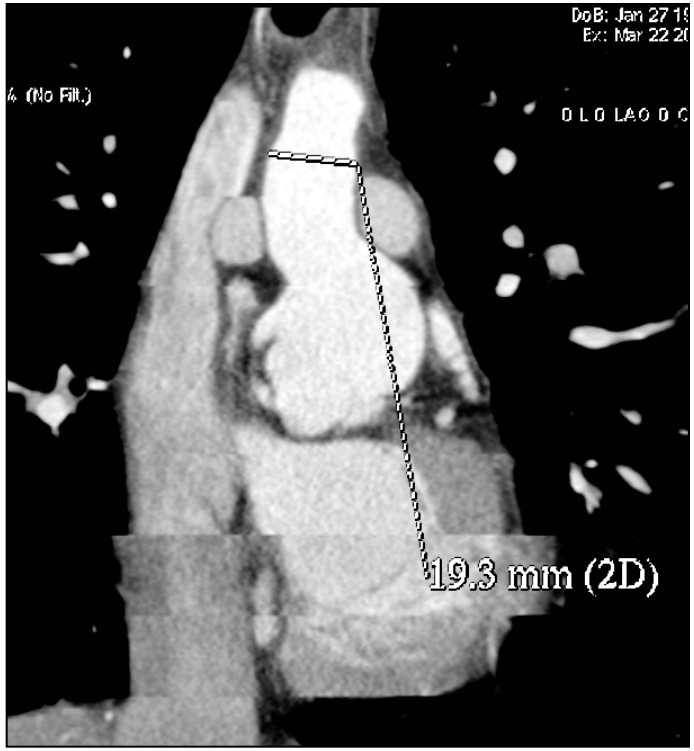
(No Filt.)
19.3 mm (2D)

S
IVA
I

TGV: switch artériel

- sténoses et étirement des artères pulmonaires ;
- les anomalies de réimplantations des artères coronaires (sténoses, plicature, étirement) : mort subite
- dilatation du culot aortique

Scanner synchronisé à l'ECG +++

Cardiopathies congénitales

- Tétralogie de Fallot
- Atrésies pulmonaires
- Transposition des gros vaisseaux
- **Double discordance**
- Maladie d’Ebstein
- Ventricule unique

Double Discordance

- 1% des CP congénitales
- VD systémique
- Malformations associées:
  - CIV 70%
  - Sténose pulmonaire 40%
  - IT

Discordance auriculo-ventriculaire

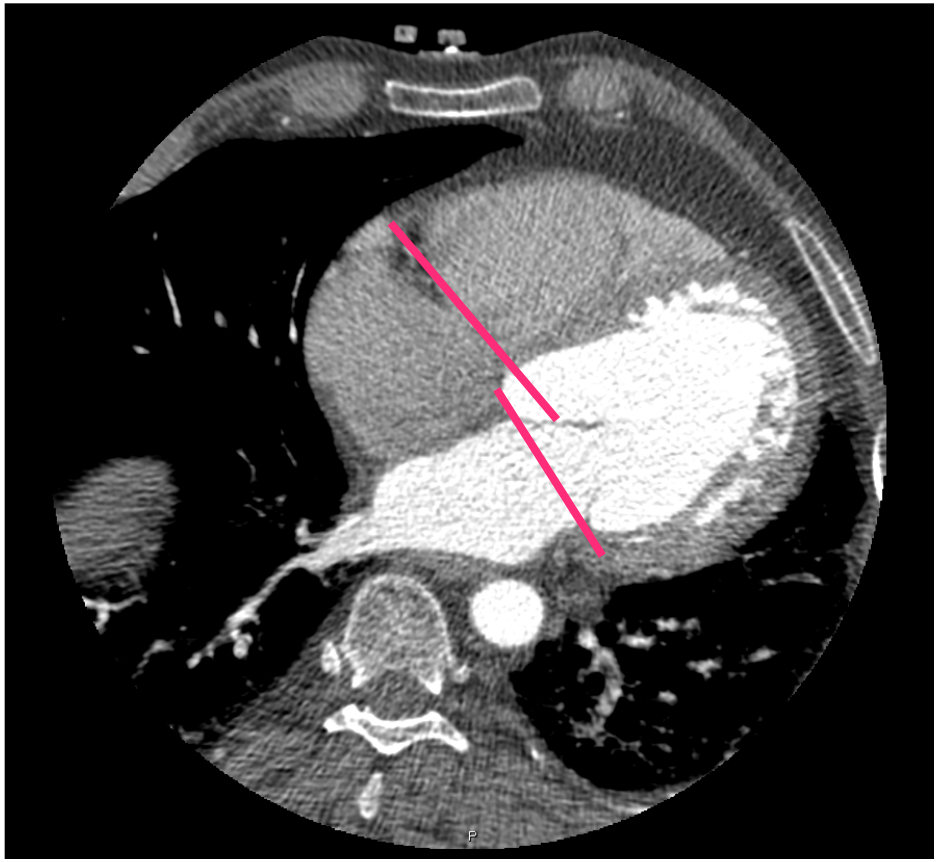

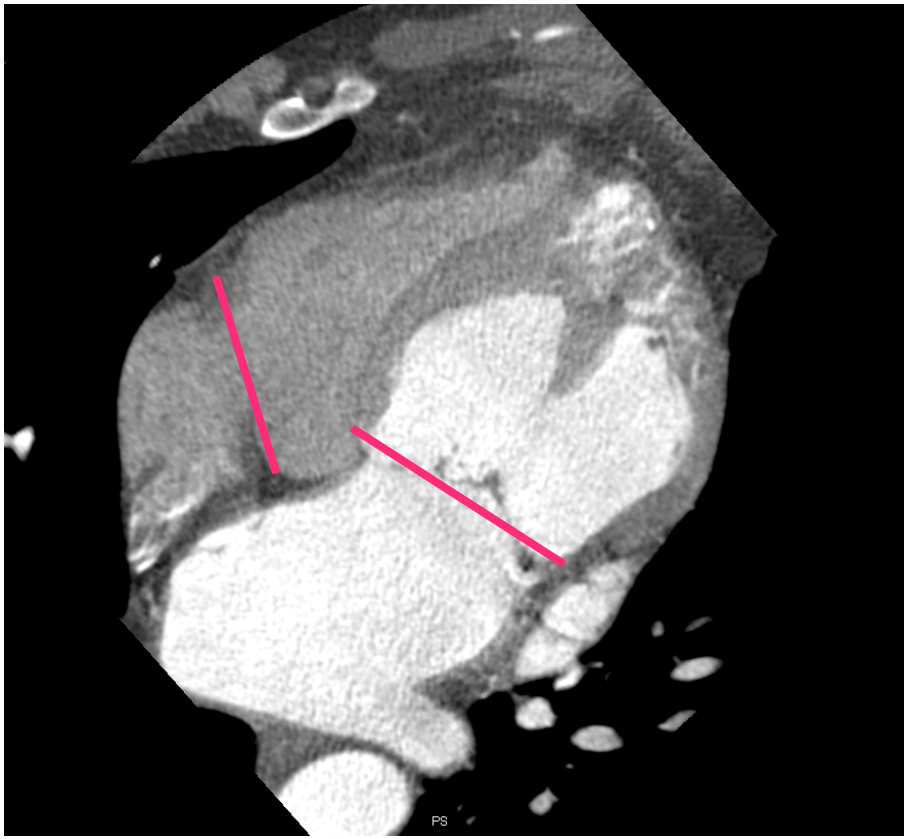

Discordance ventriculo-artérielle

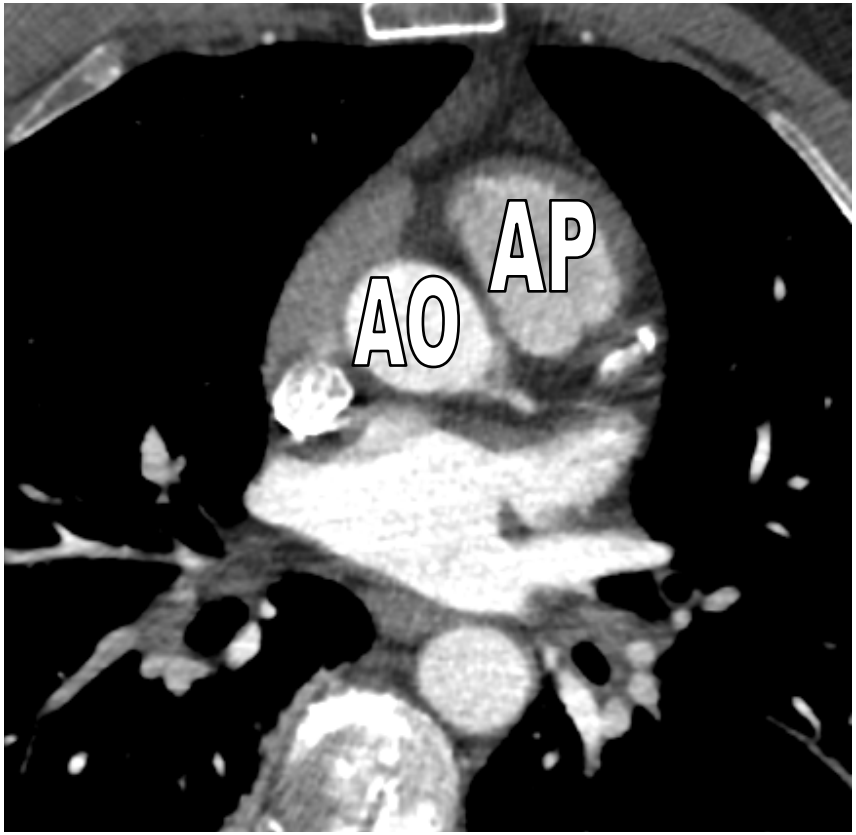

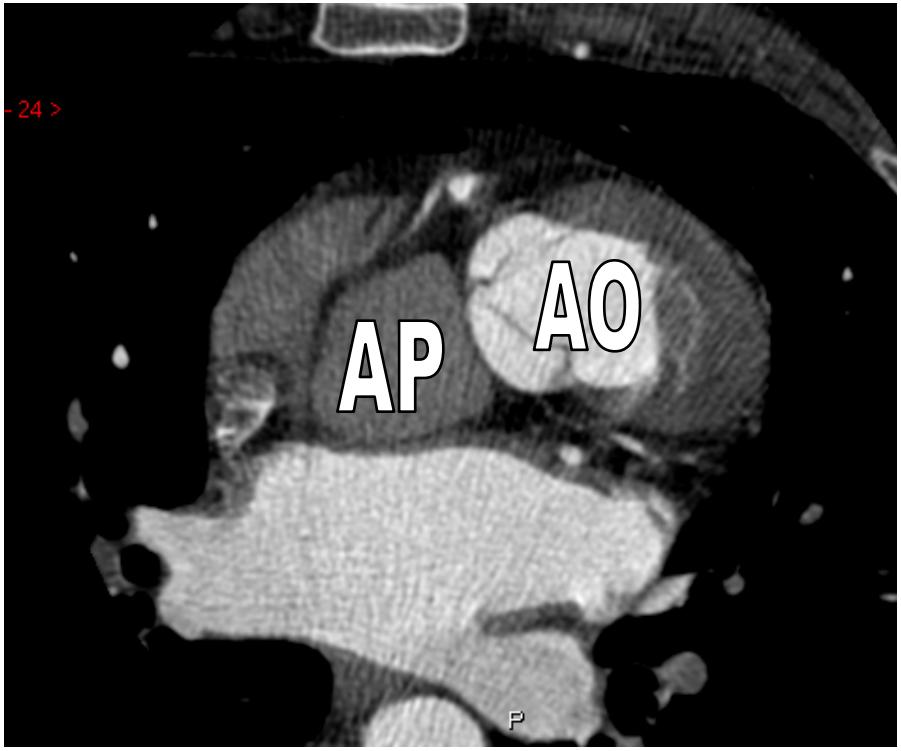

Cardiopathies congénitales

- Tétralogie de Fallot
- Atrésies pulmonaires
- Transposition des gros vaisseaux
- Double discordance
- **Maladie d'Ebstein**
- Ventricule unique

Maladie d’Ebstein

- 0,6 % des cardiopathies congénitales

- malformation de la valve tricuspide
  - défaut de délamination de ses feuillets pendant le développement embryonnaire
  - excès de tissu valvulaire tricuspide
  - adhérence d’une portion variable des valves septale et postéro- inférieure à la paroi du VD

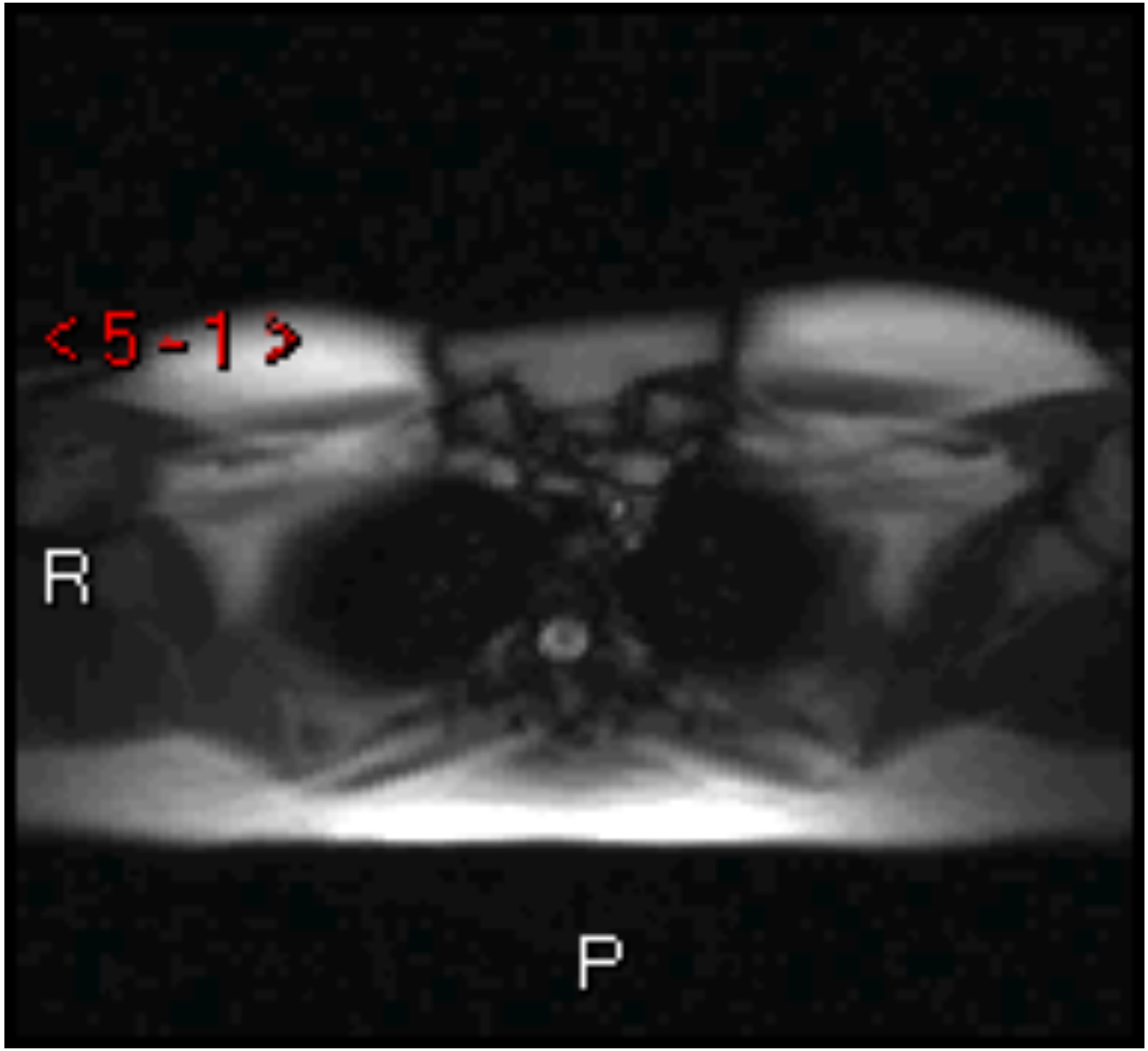
<5-1>
R
P

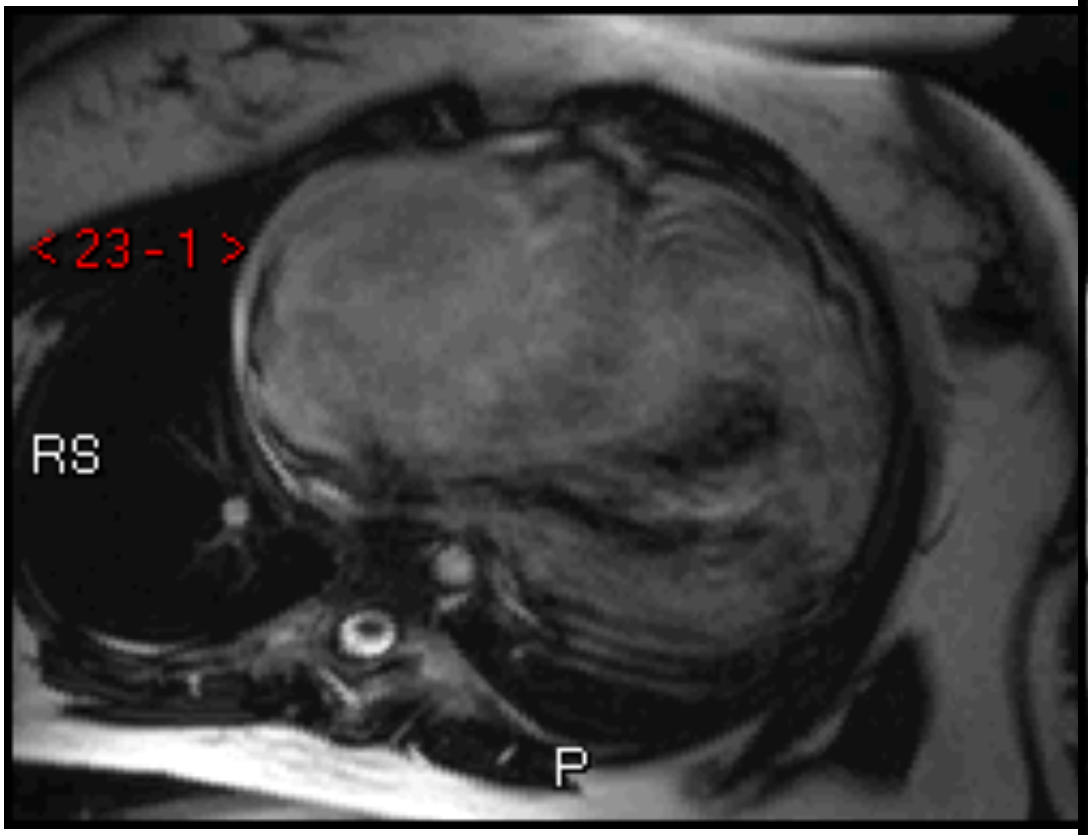
<23-1>
RS
P

<13-1>
A
I

Maladie d’Ebstein

- « Atrialisation » de tout ou partie de la chambre d’admission du VD
- Amincissement de la paroi myocardique VD
- Dilatation de l’oreillette droite
- Valve tricuspide peut être très souvent insuffisante ou parfois sténotique, ou encore les deux

IRM

- bilan préopératoire
  - Plastie ou remplacement de la valve tricuspide
  - Dérivation cavo-pulmonaire

- volumes du ventricule droit
- Volumes de l’oreillette droite
- Capacité contractile du VD

Anomalies vasculaires

- Coarctation de l’aorte
- Anomalies des arcs aortiques
- Anomalies coronaires

Anomalies vasculaires

- **Coarctation de l'aorte**
- Anomalies des arcs aortiques
- Anomalies coronaires

Coarctation

- 4 à 6 / 10 000 naissances
- 6 à 8% de l'ensemble des cardiopathies congénitales

Coarctation

Diagnostic et bilan pré-opératoire:

- Bilan anatomique
- Stratégie opératoire
- Complications associées (hypoplasie de l'arche)

- TDM non synchro ou
- **IRM**
  - Bilan anatomique
  - Contraction
  - Valve, voie sous aortique

Surveillance post-opératoire: IRM+++

- Résultat chirurgical
- Complications:
  - Recoarctation
  - Hypolasie résiduelle
  - Faux anévrysme

Coarctation

Coarctation: IRM fonctionnelle

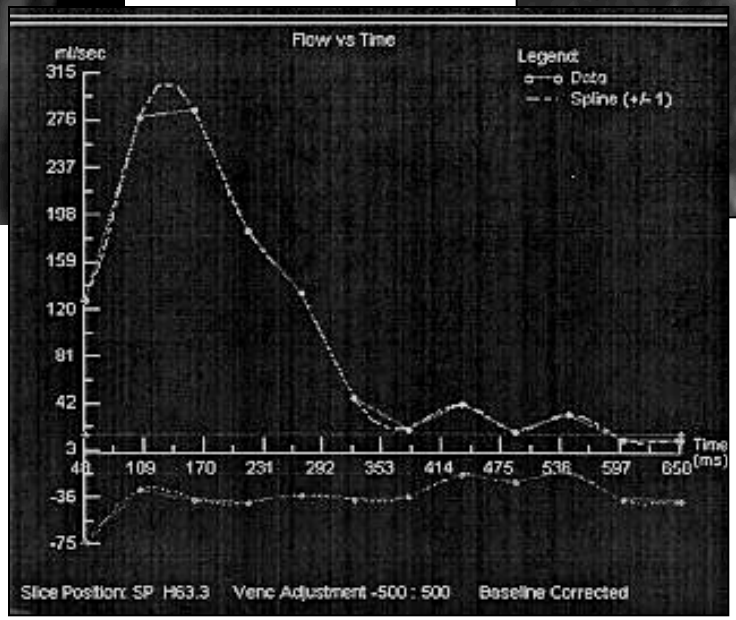

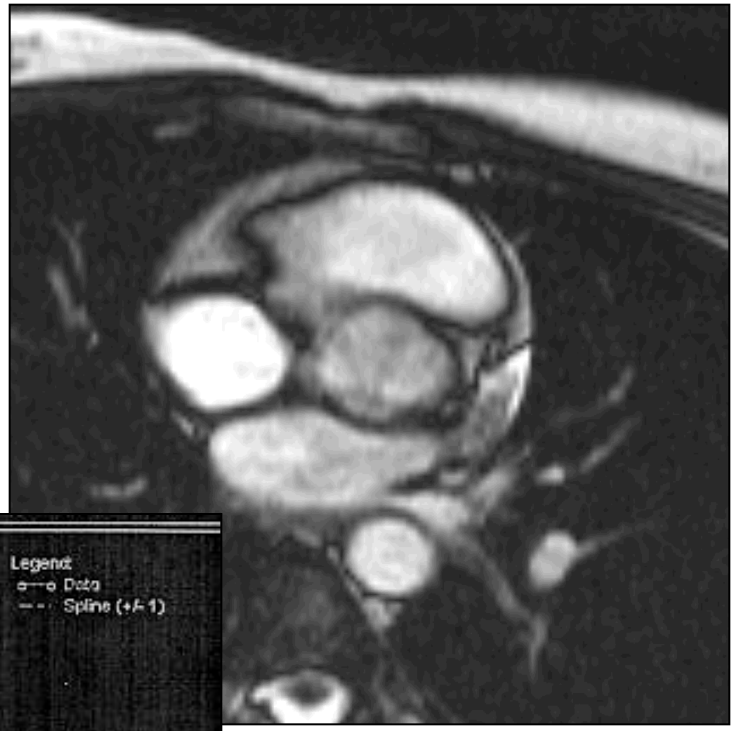

Coarctation: IRM fonctionnelle



Patient Height: ---- cm. Patient Weight: 66.00 kg. Heart Rate: 69 Beats/m

Slice Position: SP H62.5 Region: 1
Range,ms: 0 to 710 Venc Adjustment -500 cm/sec 500 cm/sec
Body Surface Area (BSA): ---- m^2

Velocity
Peak Velocity: -245.21 cm/sec
Average Velocity: -11.45 cm/sec

Flow
Average Flow Over Range: -51.51 ml/sec
Average Flow Per Minute: -2.52 l/min

Forward Volume: 1.75 ml
Reverse Volume: 38.32 ml
Net Forward Volume: -36.57 ml
Net Forward Volume / BSA: ---- ml/m^2

Coarctation

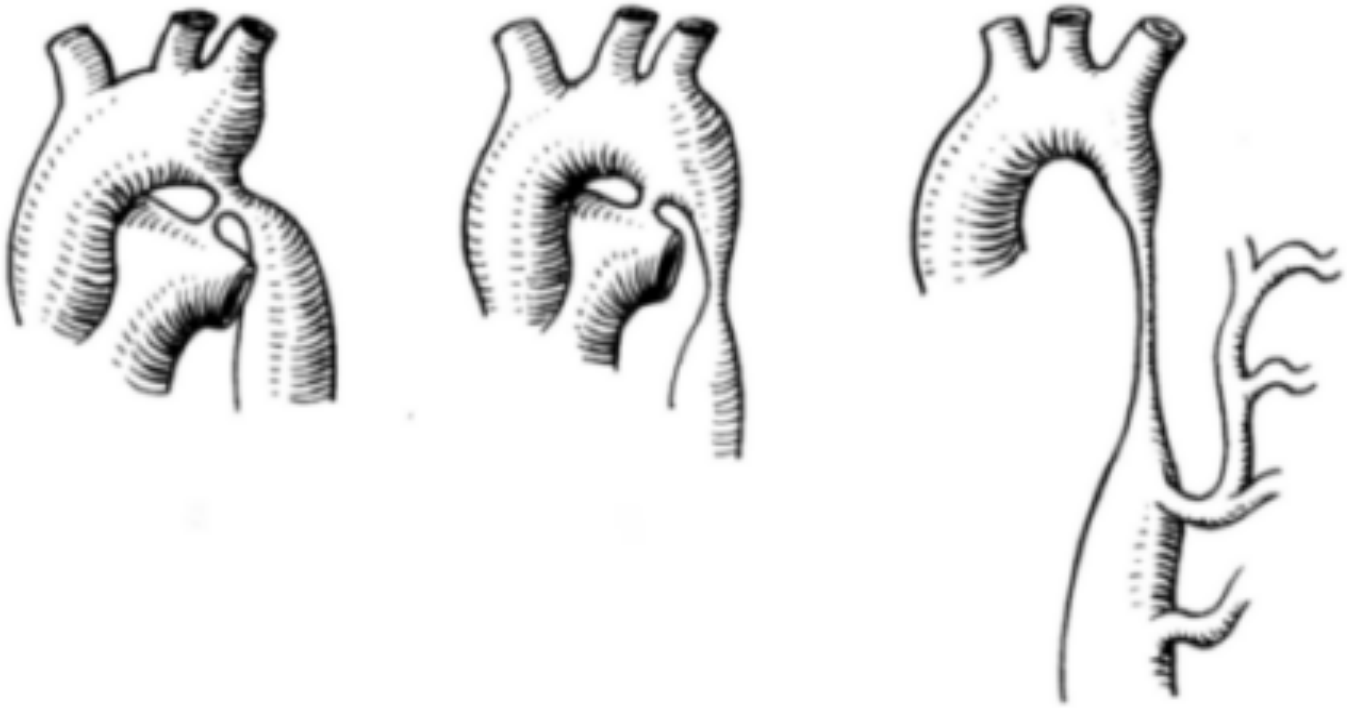

Coarctation: chirurgie

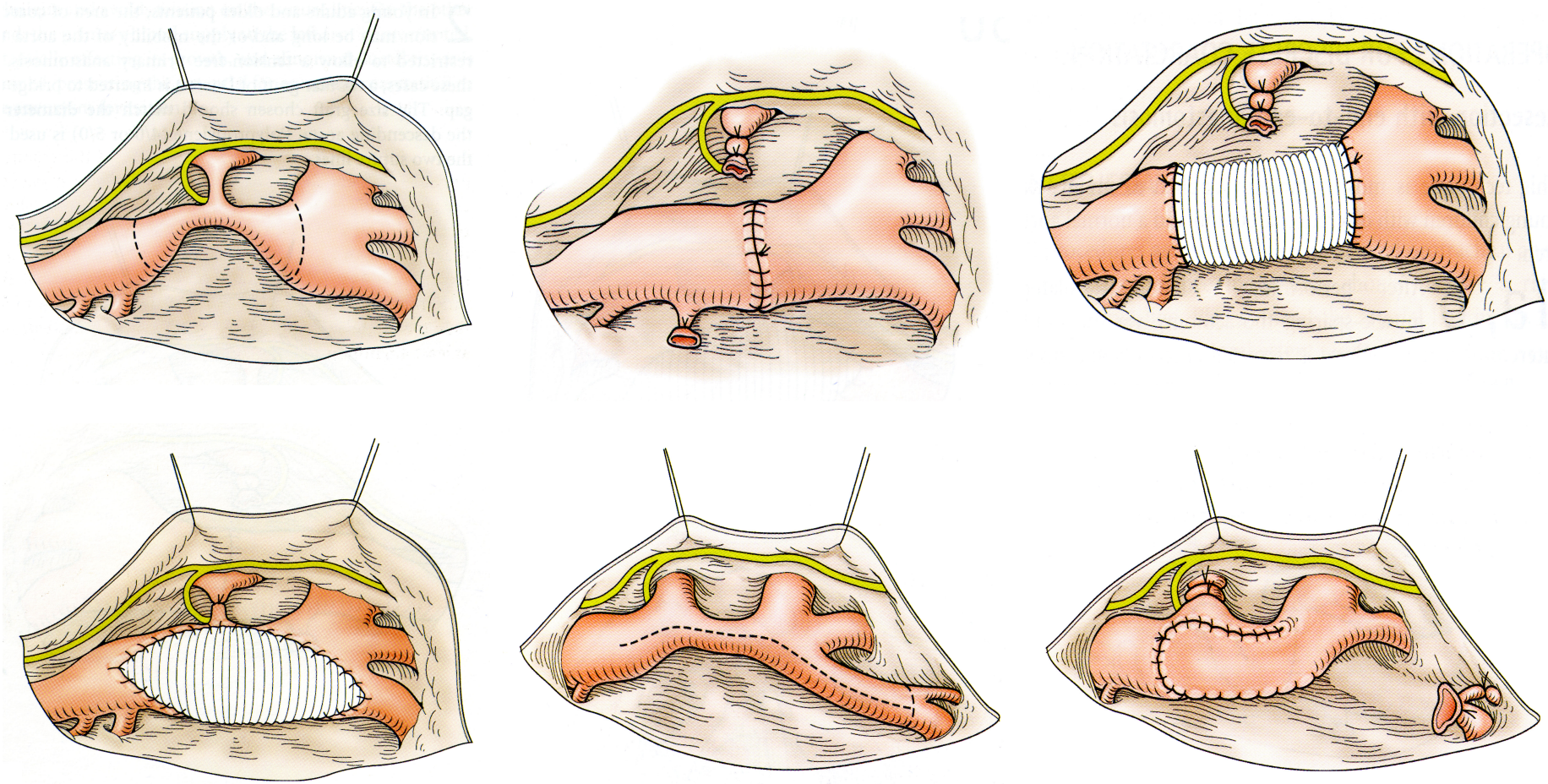

Coarctation: resténose

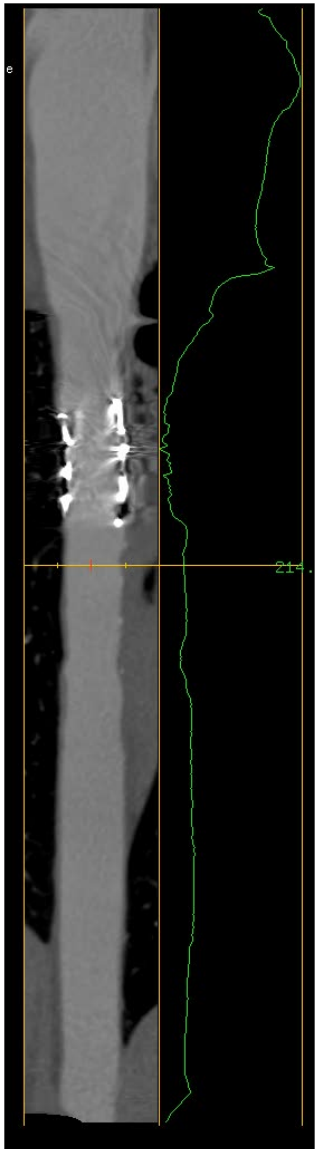

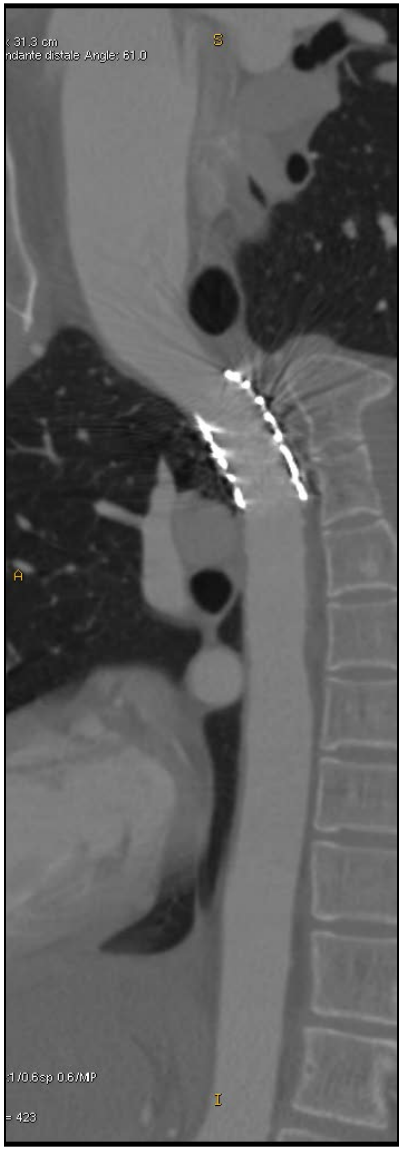

Anomalies vasculaires

- Coarctation de l’aorte
- Anomalies des arcs aortiques
- Anomalies coronaires

Anomalies des arcs aortiques

- Malformations congénitales (30%)
- Origine embryologique commune
- Axes vasculaires dérivant des arcs branchiaux primitifs

- **TDM et IRM:**
  - Bilan anatomique
  - Complications

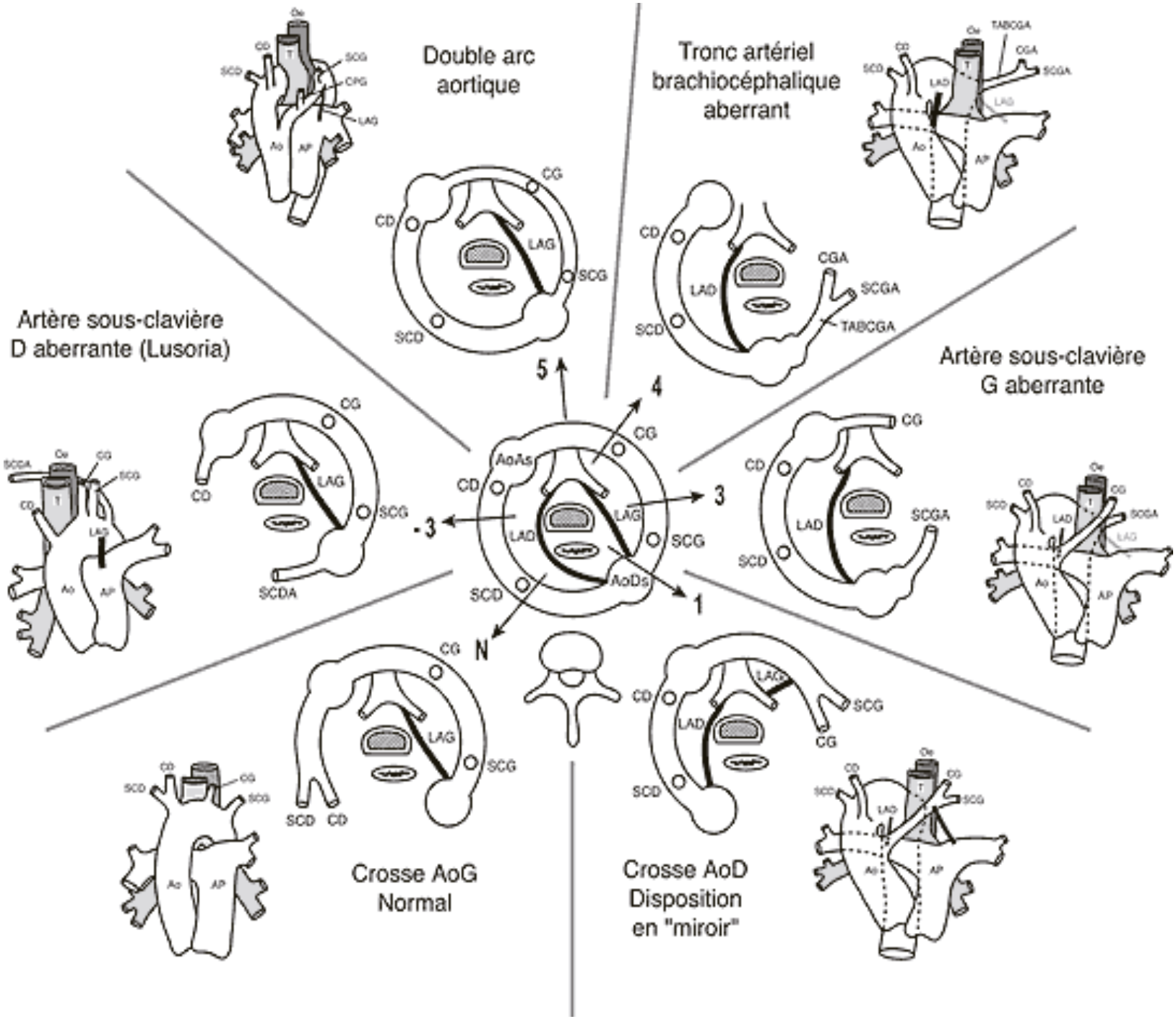
Double arc aortique
Tronc artériel brachiocéphalique aberrant
Artère sous-clavière D aberrante (Lusoria)
Artère sous-clavière G aberrante
Crosse AoG Normal
Crosse AoD Disposition en "miroir"
5
4
3
-3
1
N
CG
CD
SCD
LAG
SCG
LAD
CGA
SCGA
TABCGA
SCDA
AoAs
AoDs
Ao
AP

Double arc

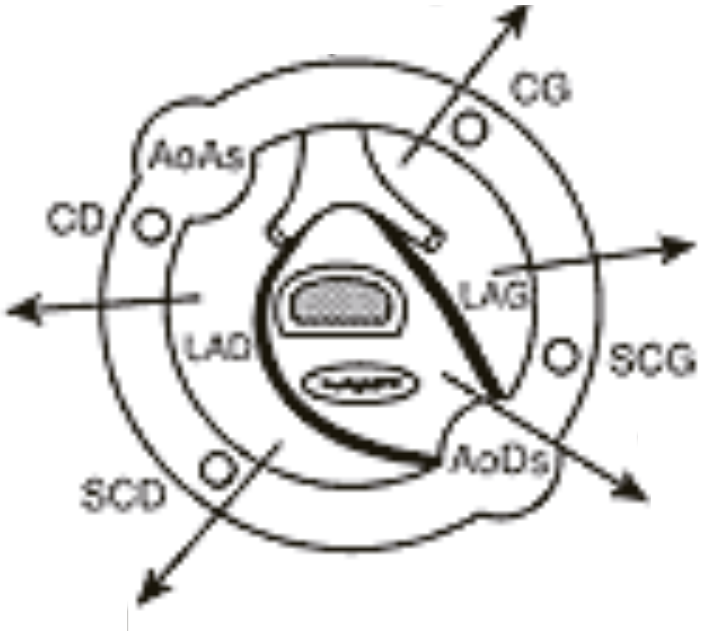

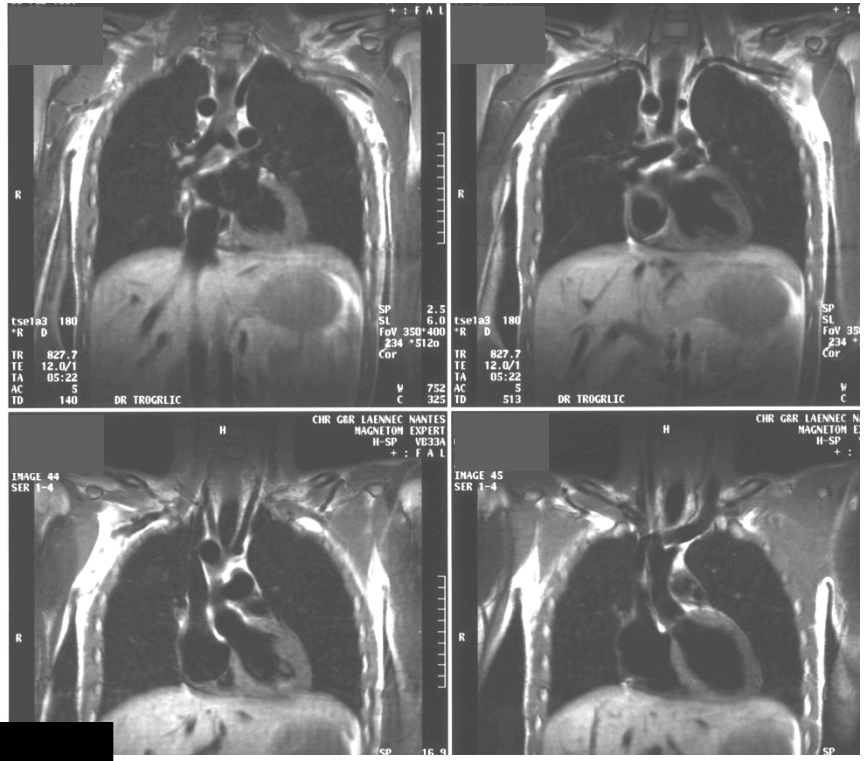

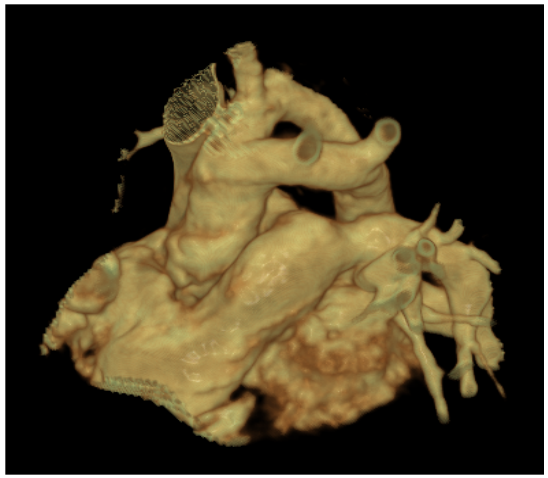

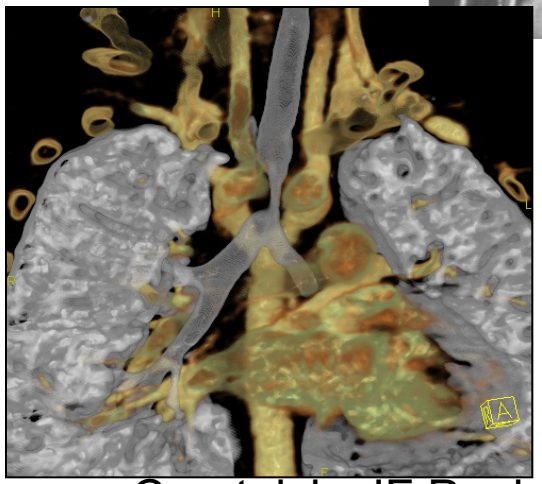

Courtoisie JF Paul

Double arc

Double arc avec atrésie de l’ AAG

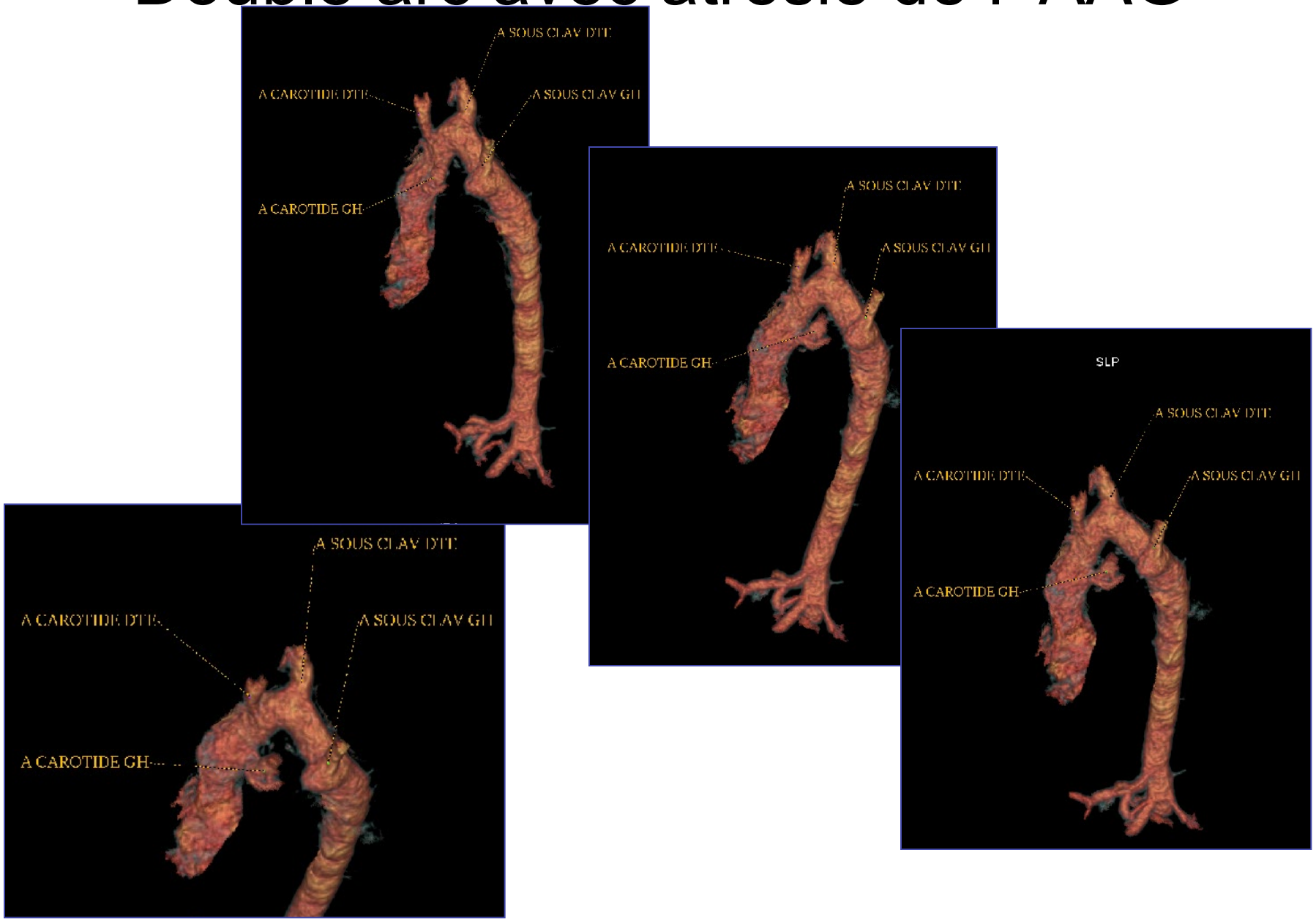

Arc aortique gauche
ASC droite rétro-oesophagienne

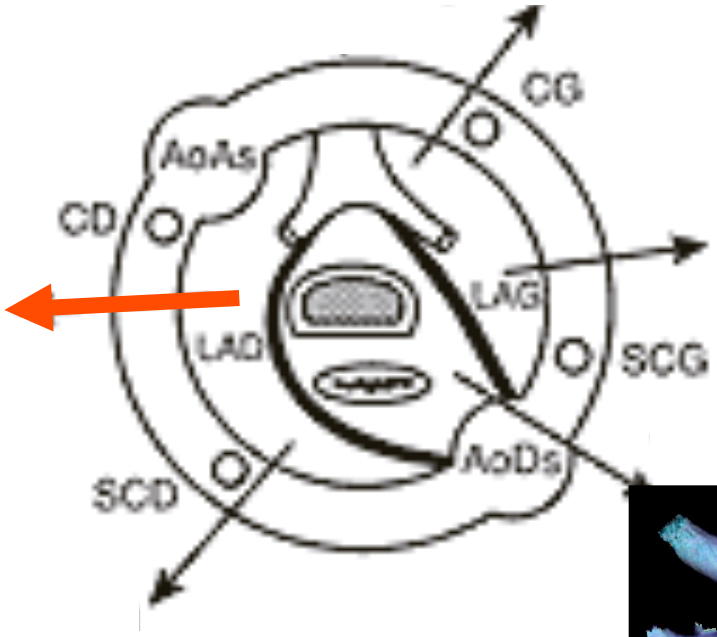

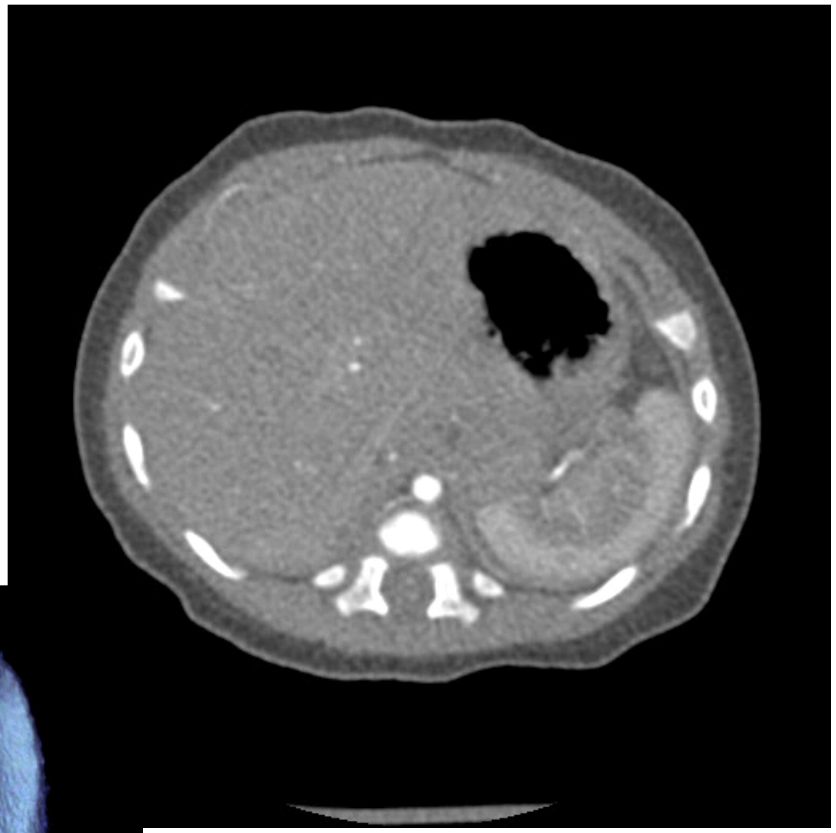

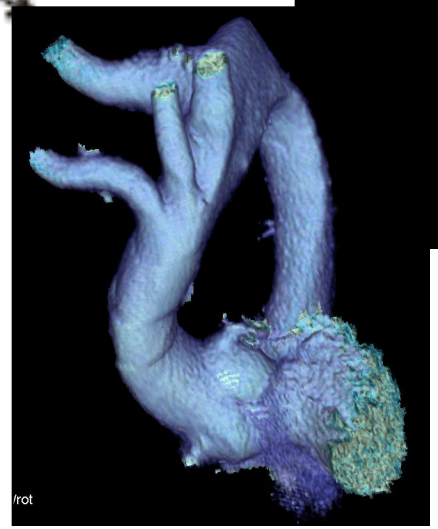

Arc aortique gauche
ASC droite rétro-oesophagienne

- Persistance d'un résidu de l'AAD:
- Diverticule de Kommerell

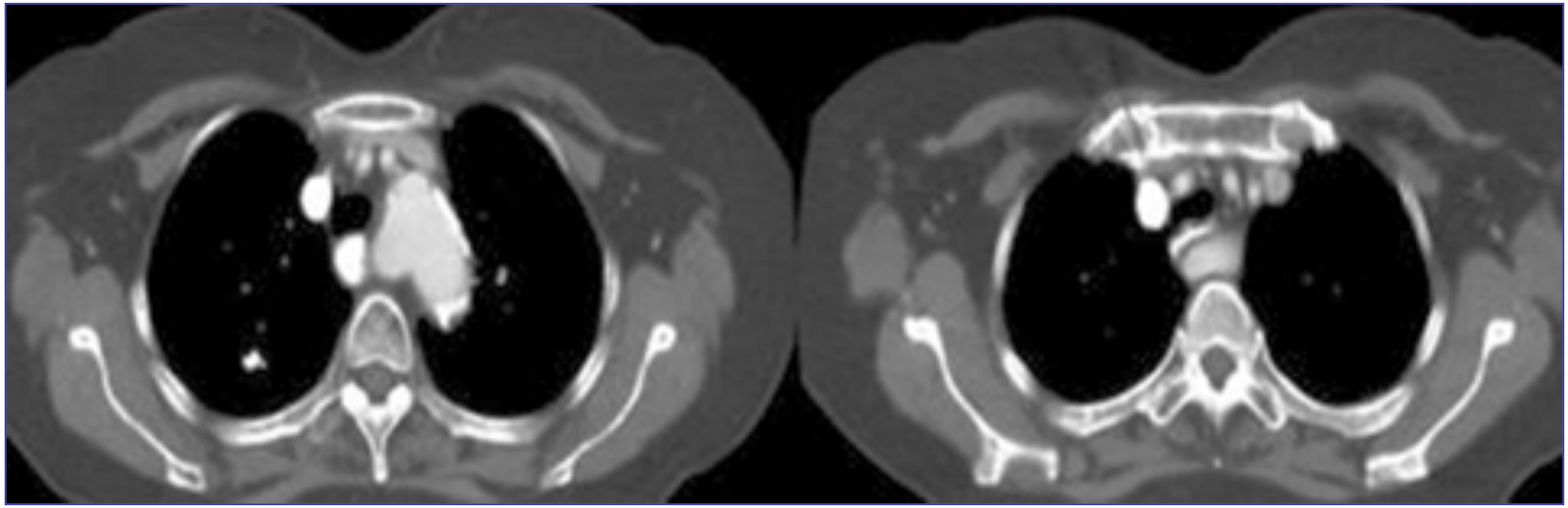

Arc aortique droit
Disposition en miroir des TSA

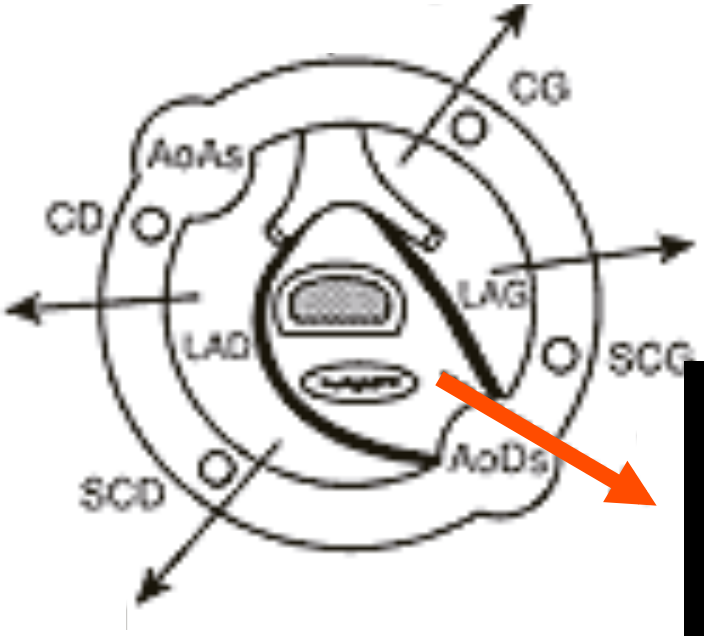

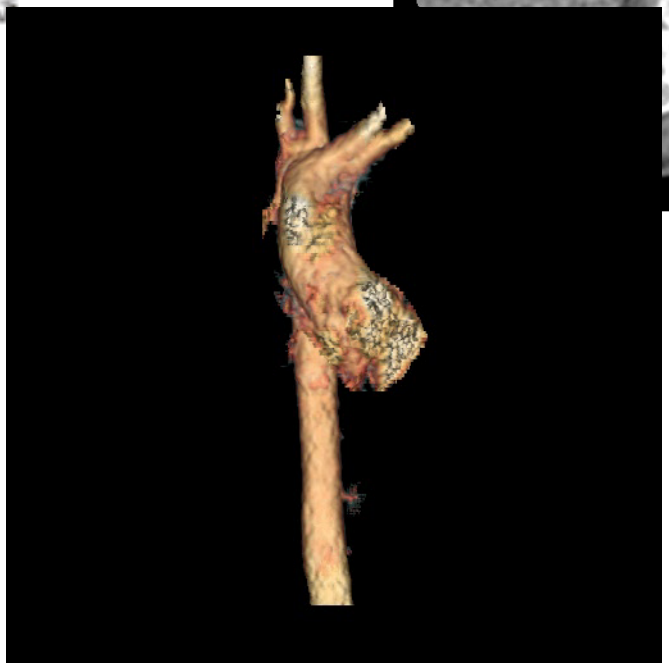

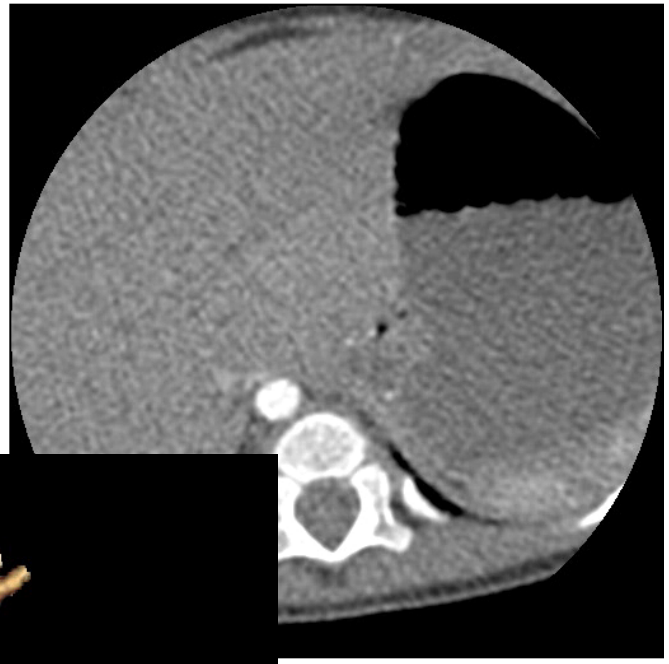

Arc aortique droit
ASC gauche rétro-oesophagienne

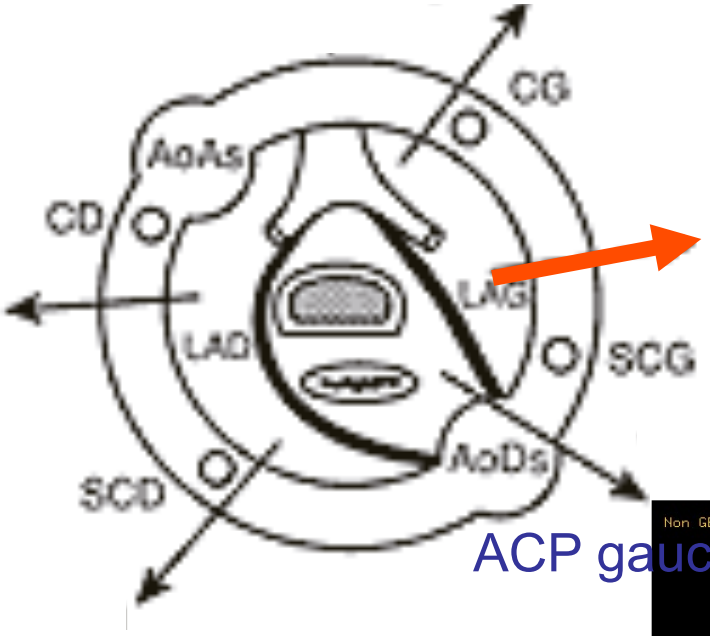

ACP droite

ACP gauche

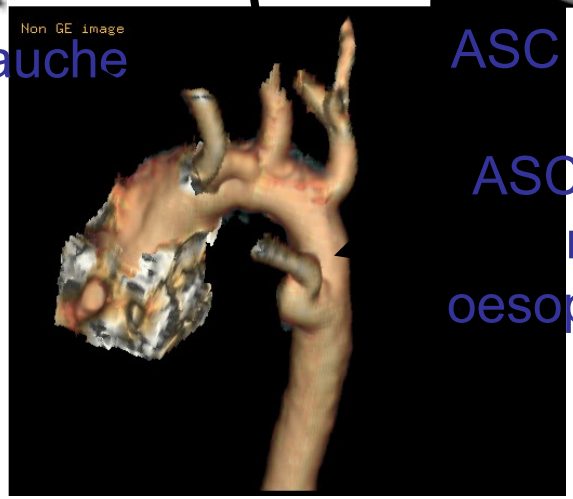

ASC droite

ASC gauche rétro-oesophagienne

Arc aortique droit
ASC gauche rétro-oesophagienne

- Associée à un résidu d'AAG: diverticule de Kommerell

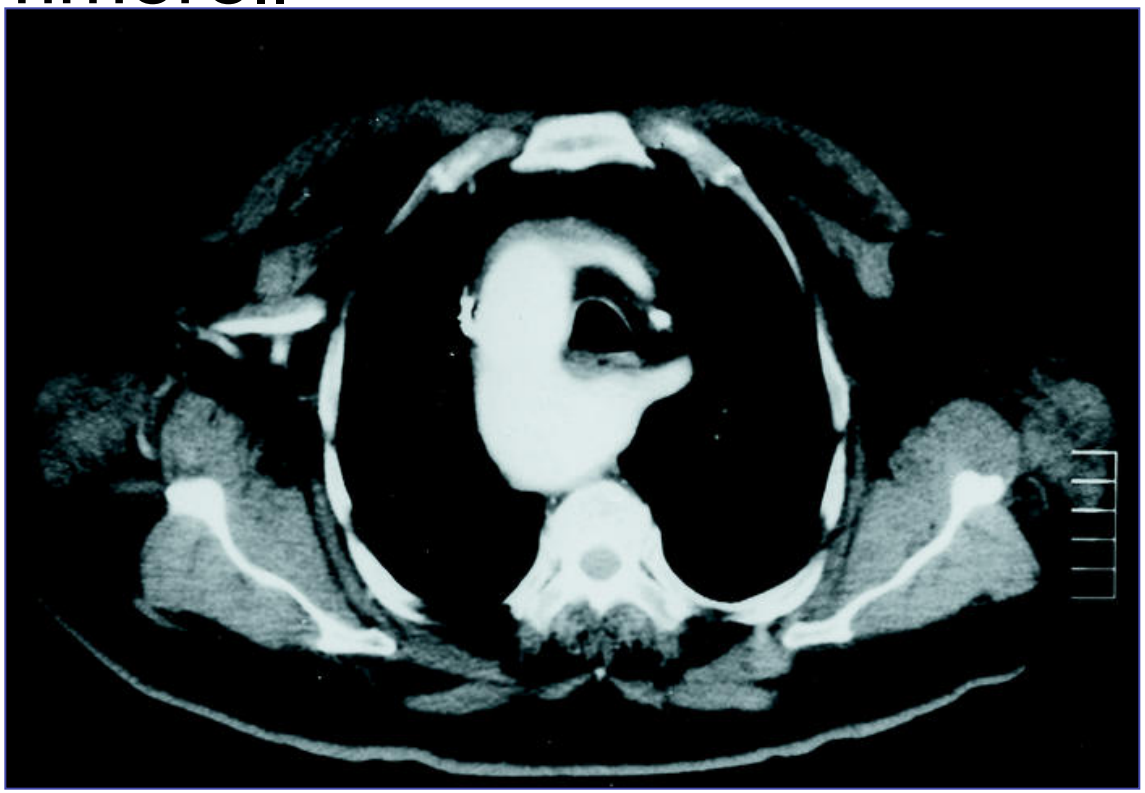

Anomalies du 6ème arc aortique

- Rare 0,54 à 1,4% des cardiopathies congénitales
- Artère pulmonaire gauche rétrotrachéale
- Absence d'une ou des 2 artères pulmonaires

- TDM non synchro ou IRM

Anomalies du 6ème arc aortique

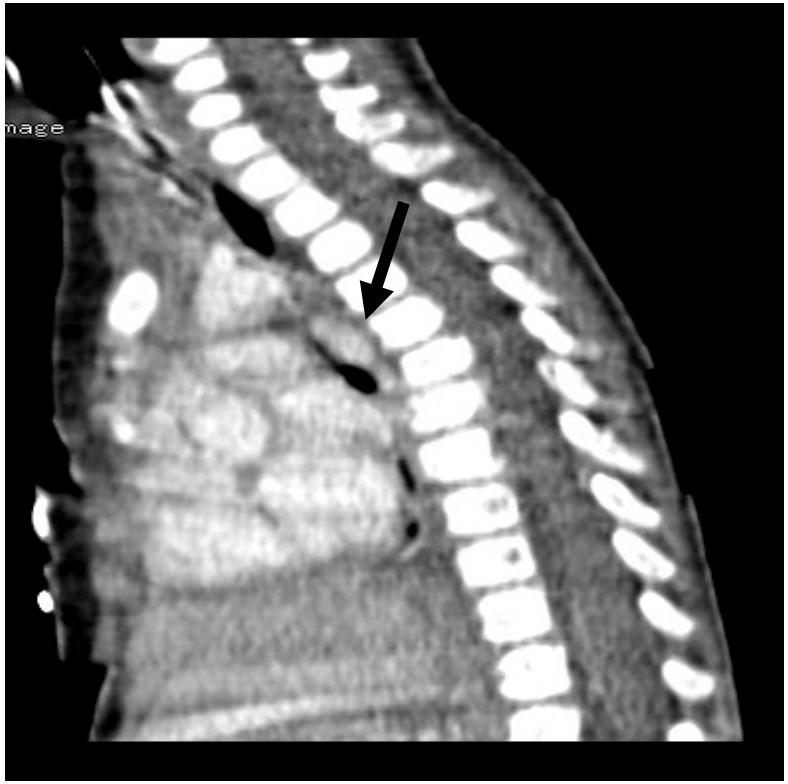

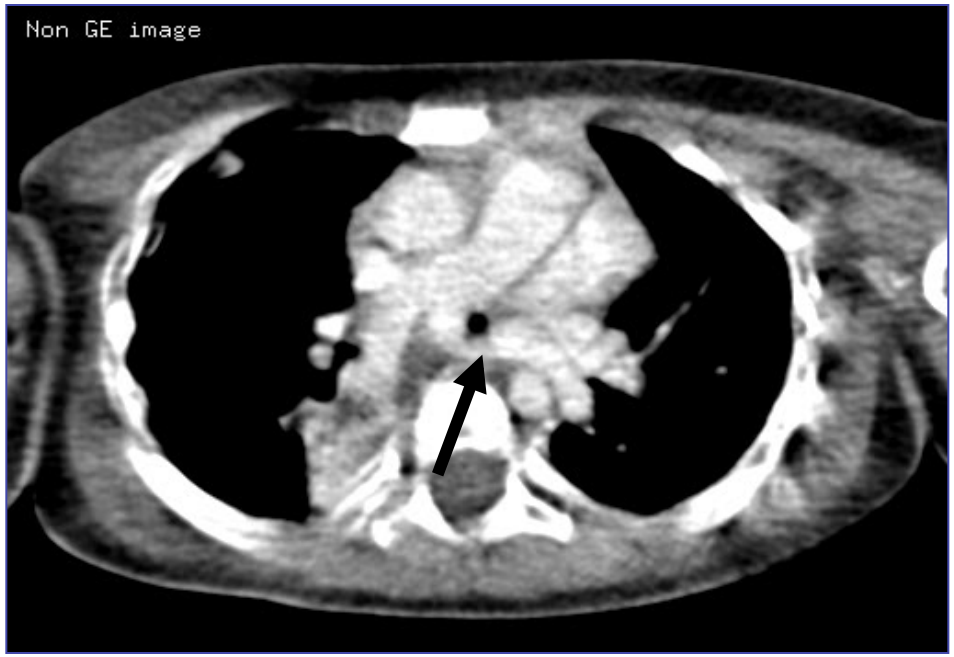

Artère pulmonaire gauche rétrotrachéale

Agénésie de l’AP

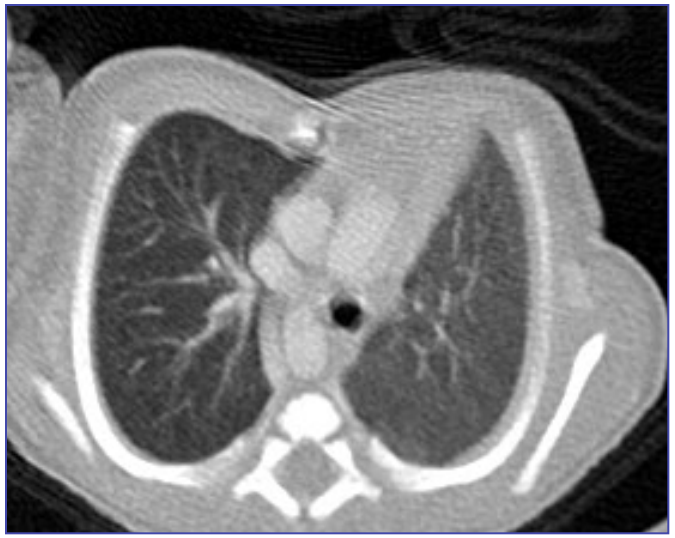

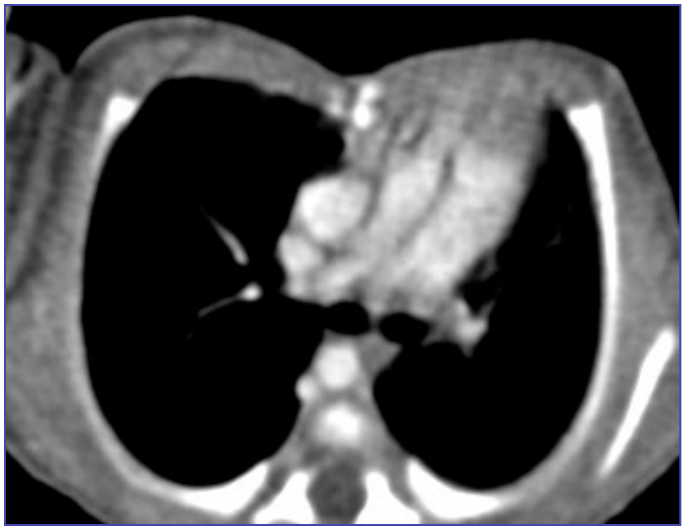

Anomalies vasculaires

- Coarctation de l’aorte
- Anomalies des arcs aortiques
- Anomalies coronaires

Anomalies coronaires

- Anomalies de naissance
  - Origine haute (take off)
  - Ostia multiples
  - Coronaire unique
  - ALCAPA

- Anomalies de trajet
  - Trajet anormal
  - Pont myocardique
  - Fistule coronaire

Anomalies coronaires

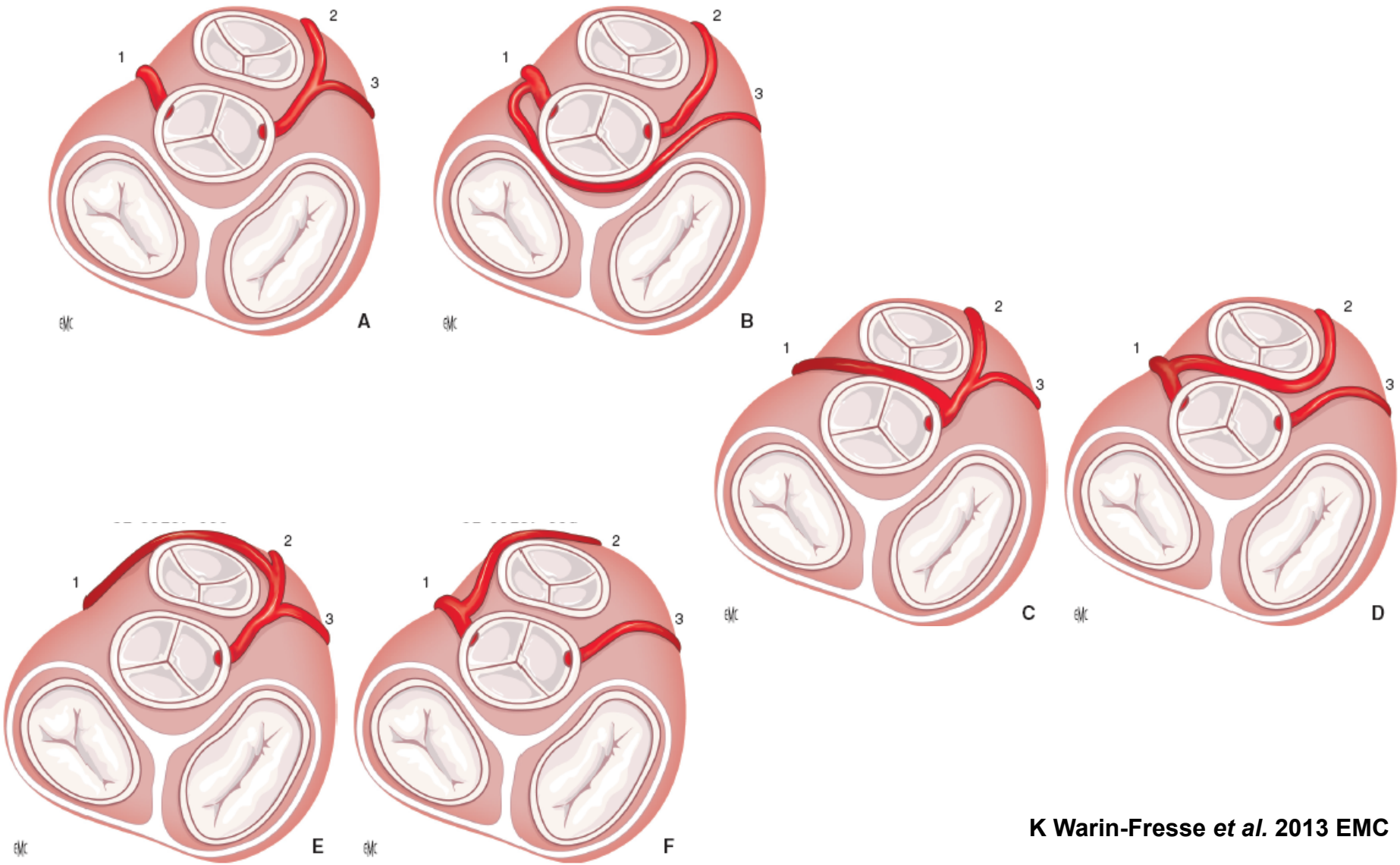

K Warin-Fresse *et al.* 2013 EMC

Hight take off

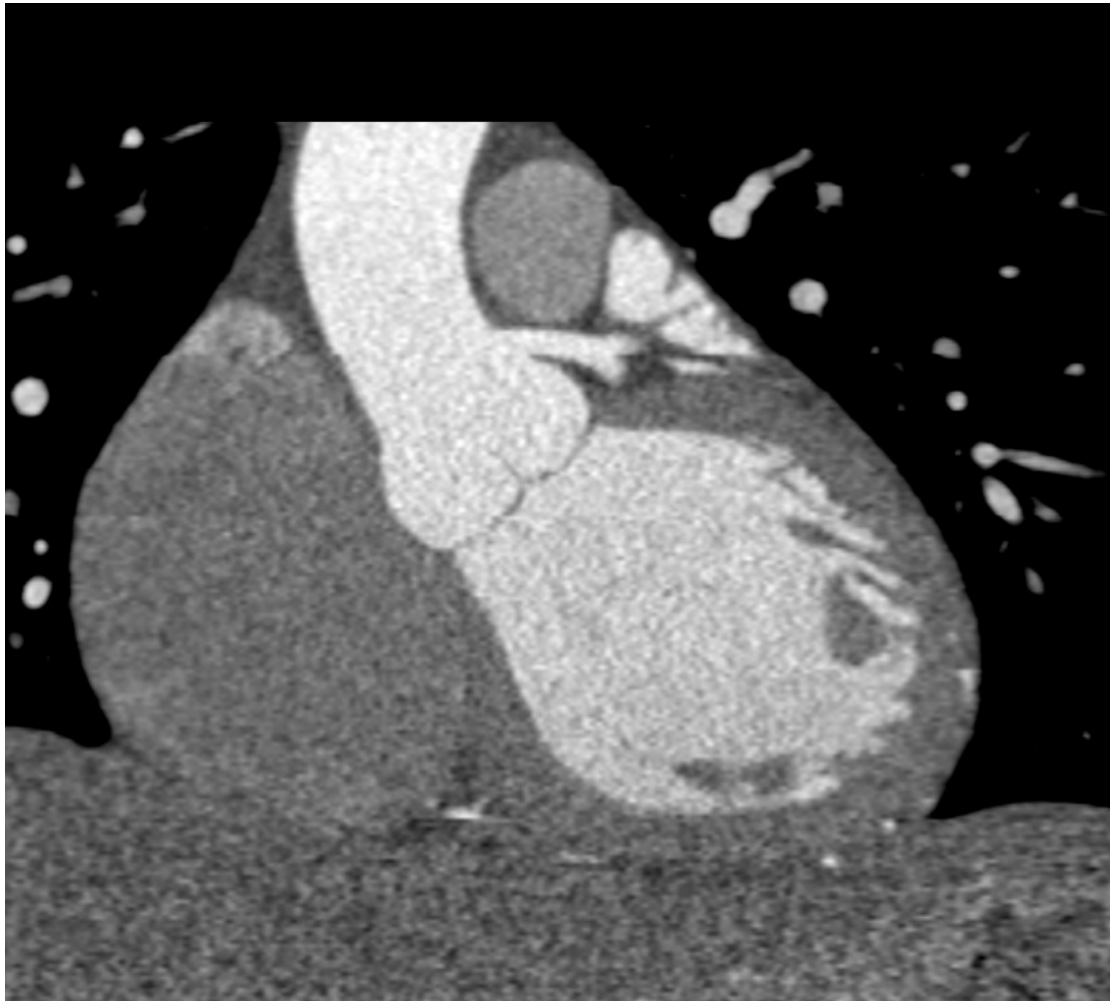

Anomalies coronaires: scanner

- Identification des ostia coronaires
- Nombre d’ostium
- Topographie des ostia
- Trajet des artères coronaires

Ostia multiples

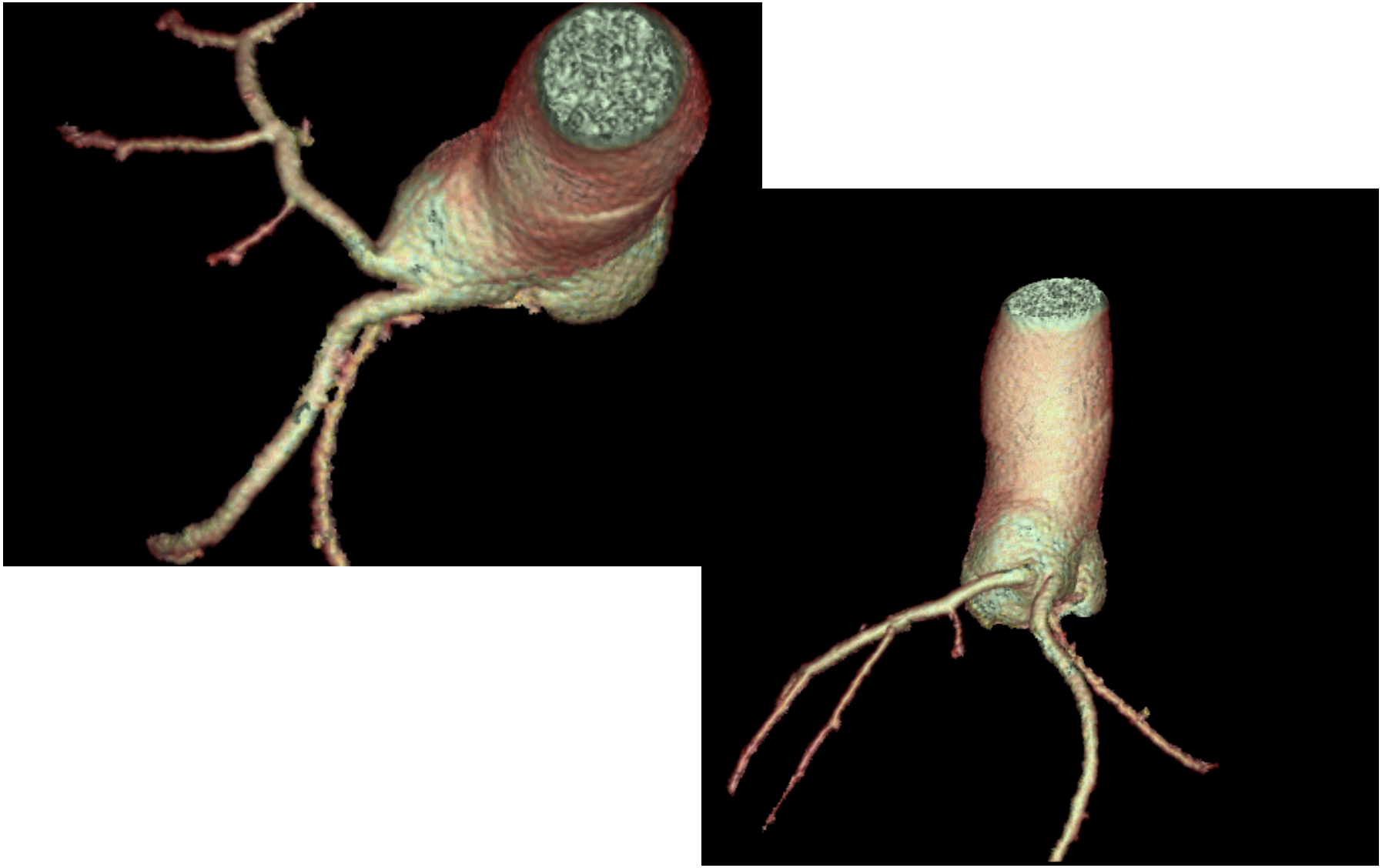

Ostia multiples

Absence de tronc commun gauche

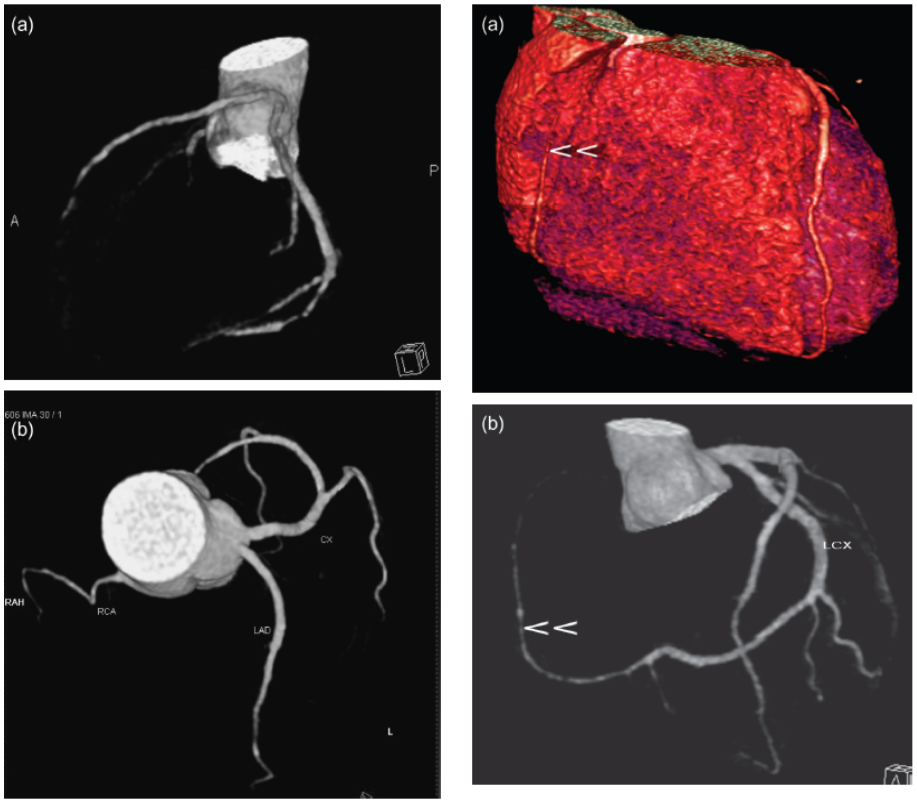

J Med Imaging and Radiation Oncol 2008

Coronaire droite
et branche infundibulaire

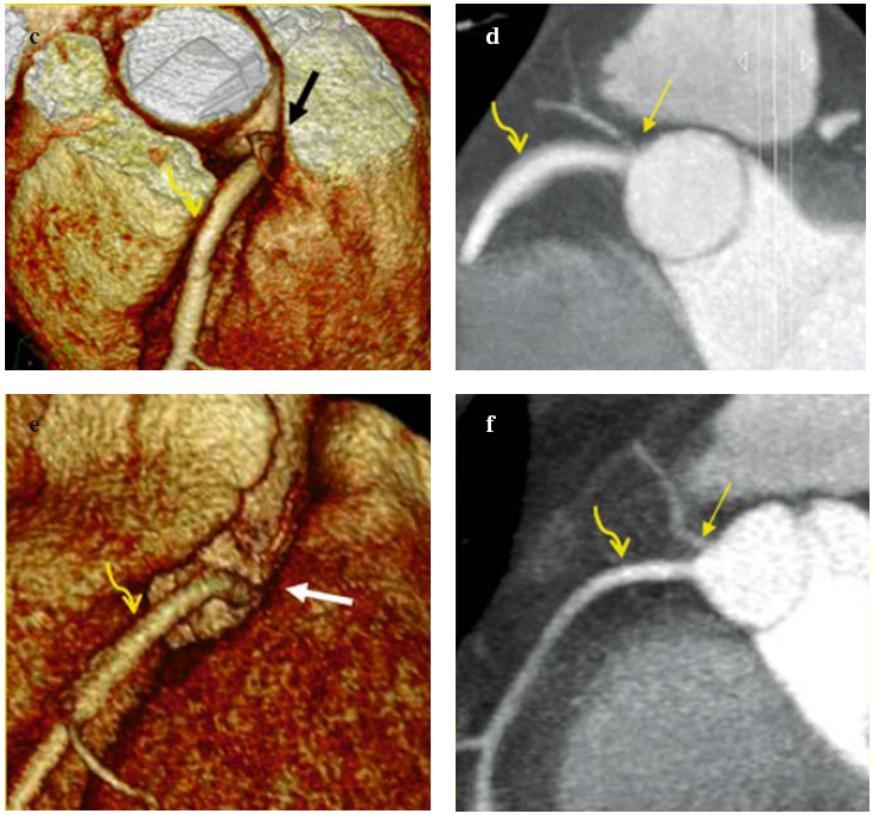

Radiol Med. 2010

Coronaire unique

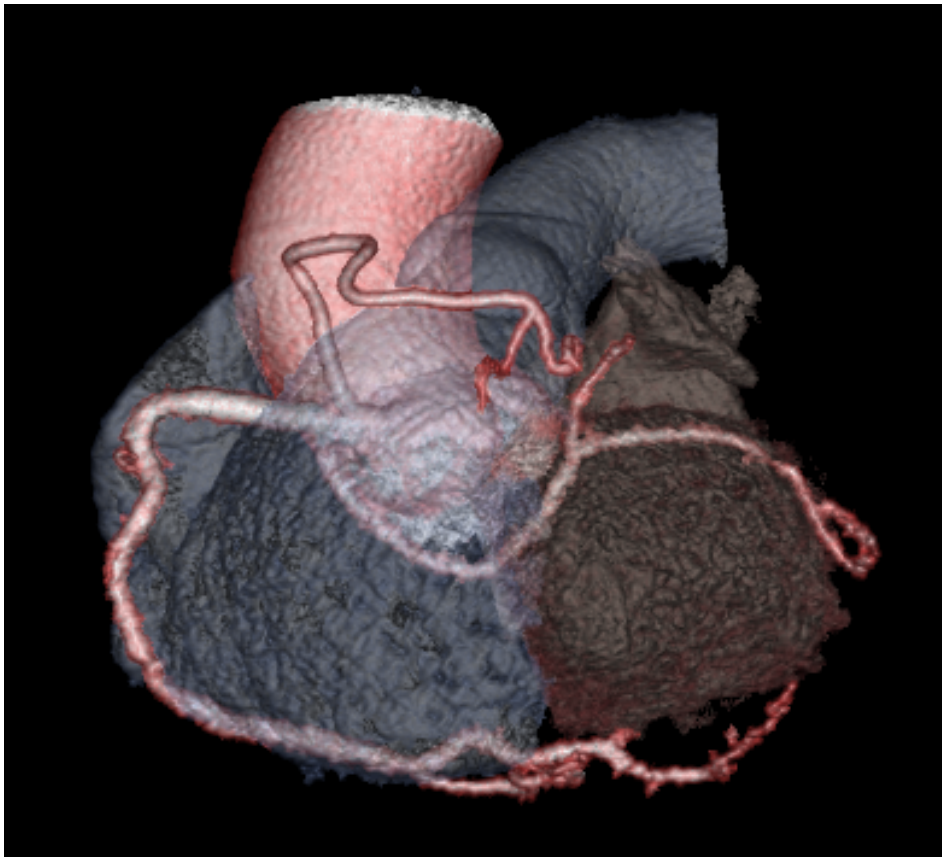

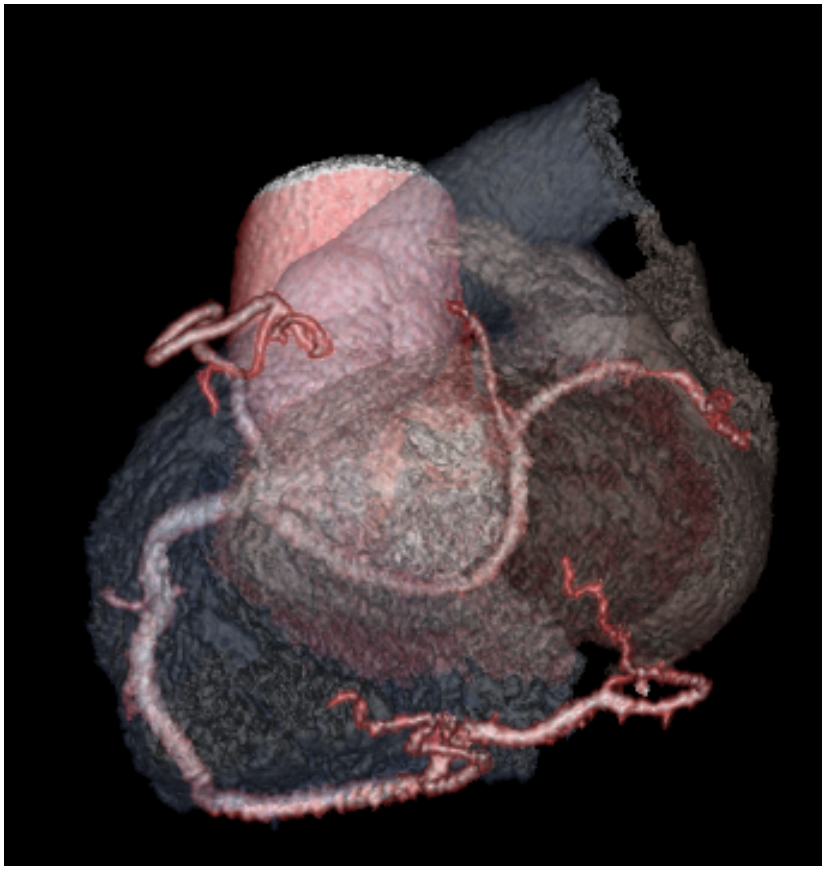

Coronaire unique

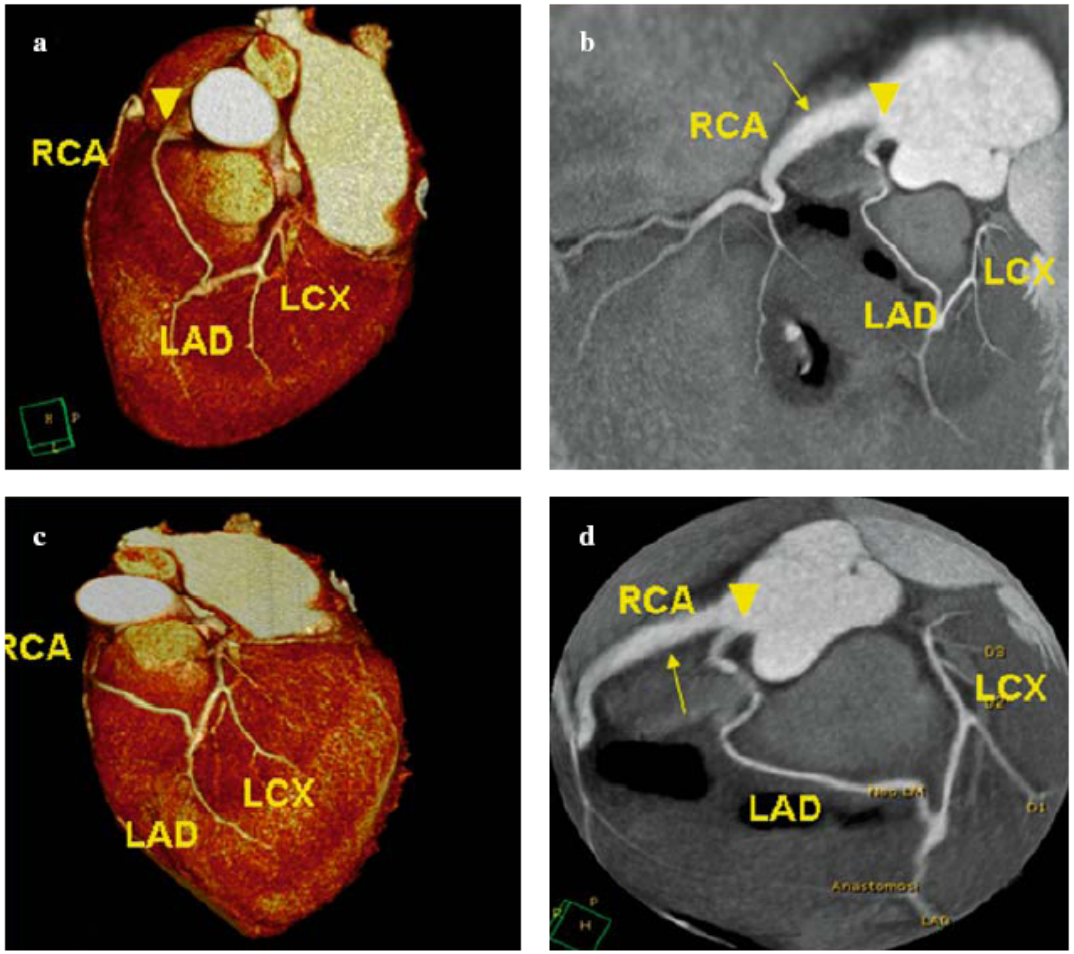

Radiol Med. 2010

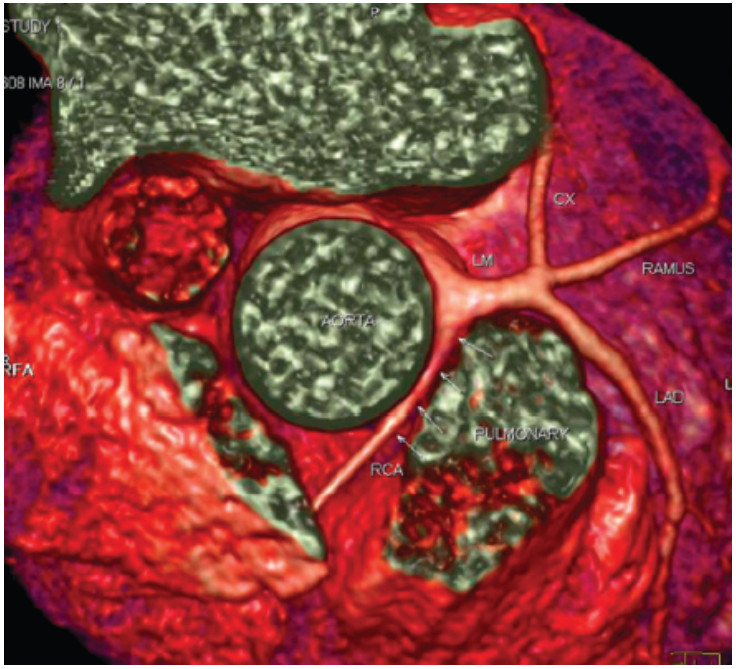

J Med Imaging and Radiation Oncol 2008

ALCAPA

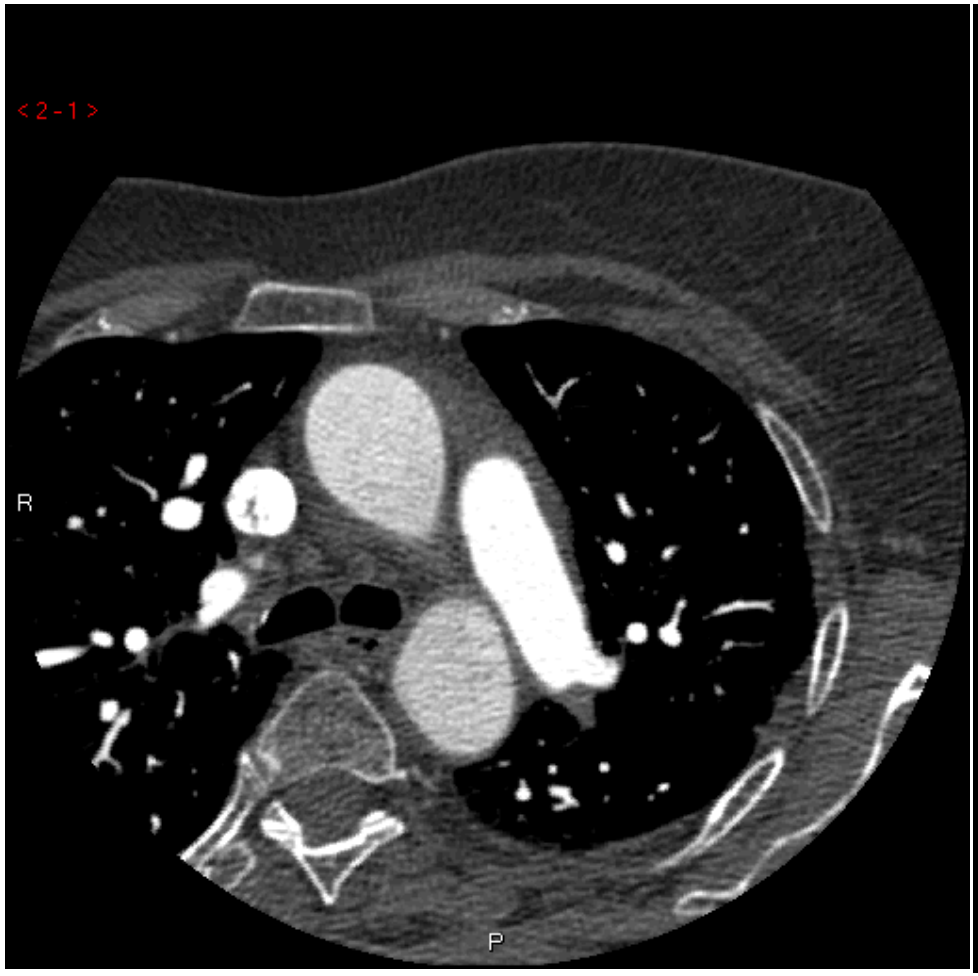

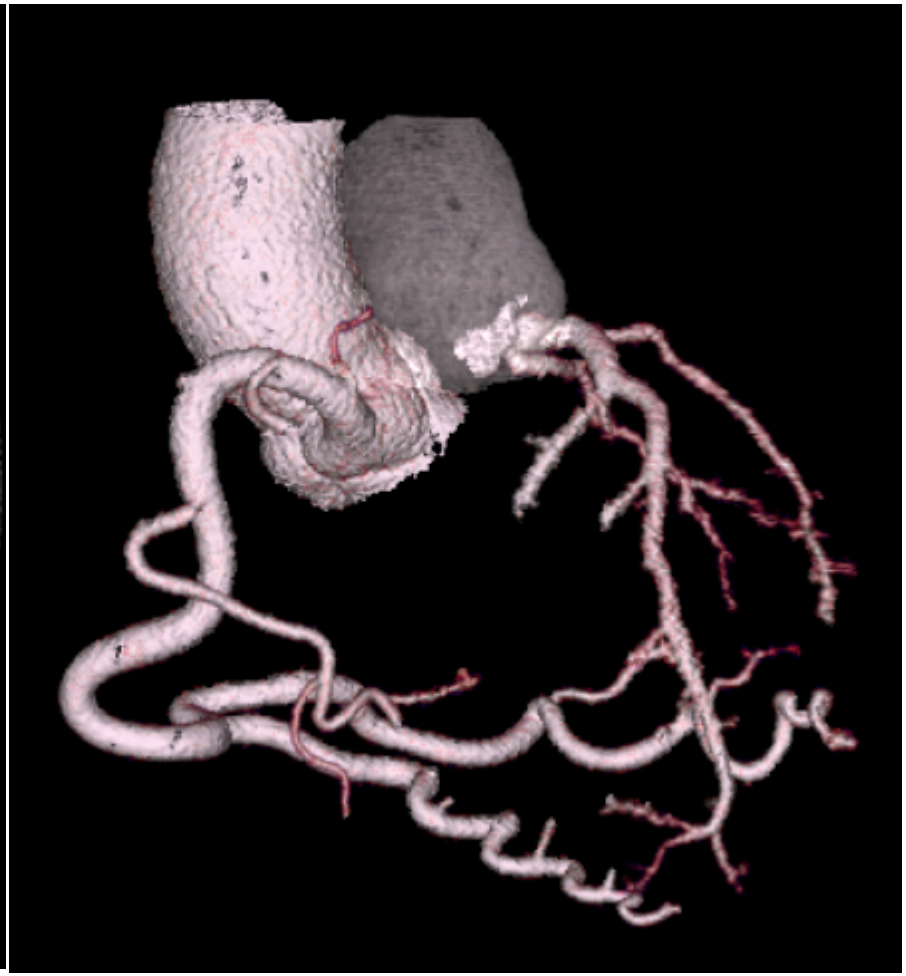

Trajet anormal

CX rétro-aortique

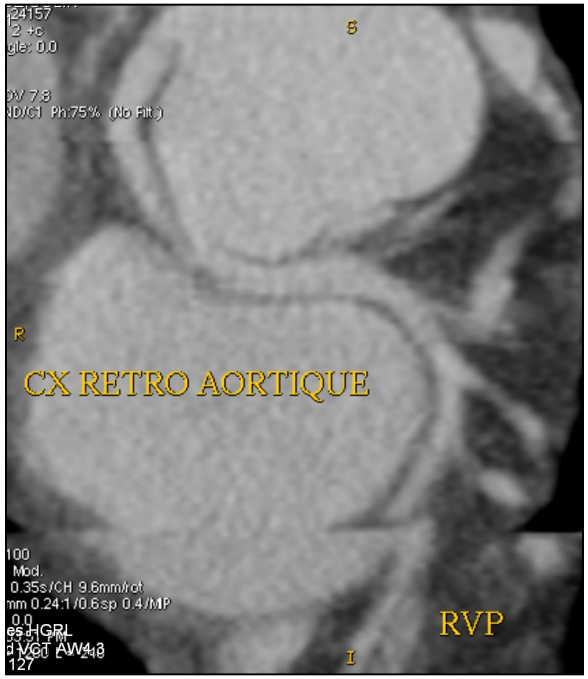

IVA Pré-pulmonaire

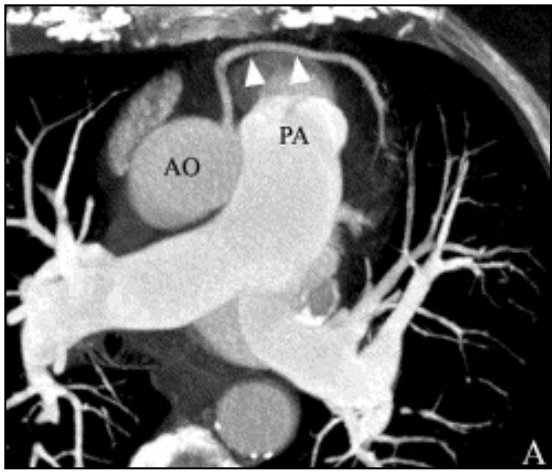

CD Inter-aortico-pulmonaire

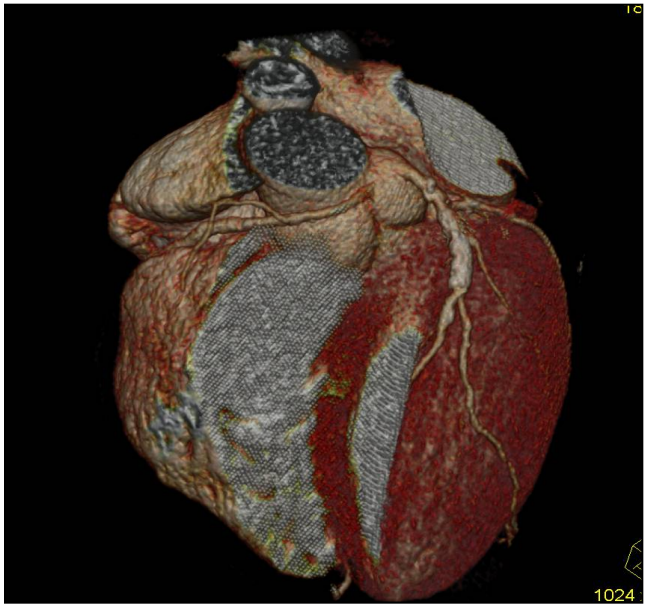

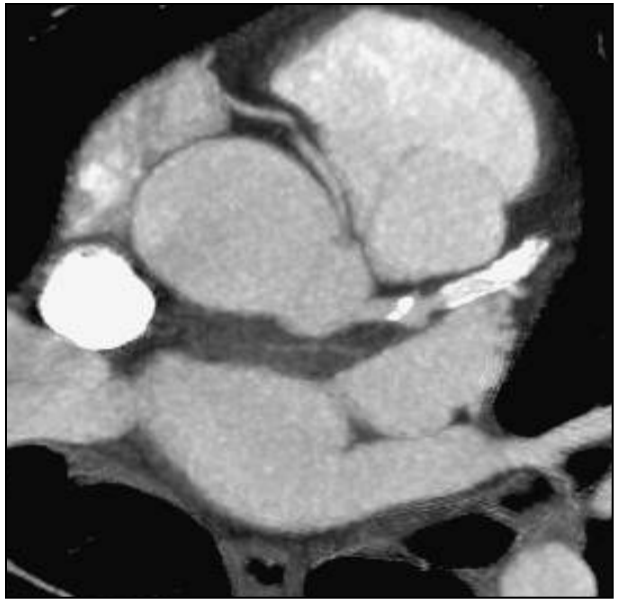

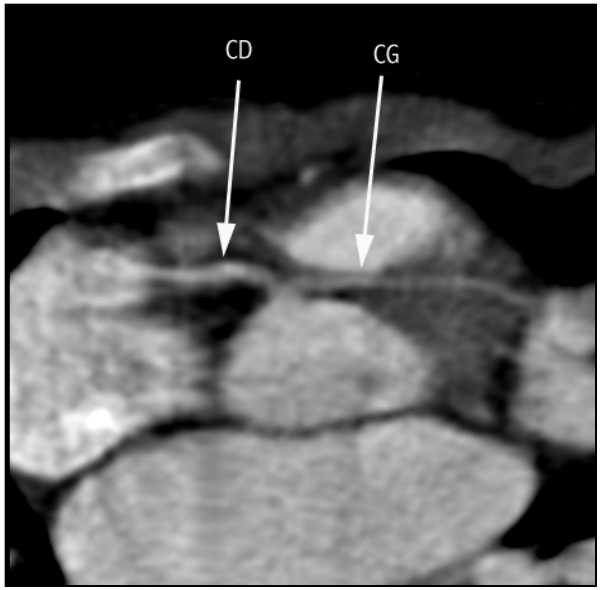

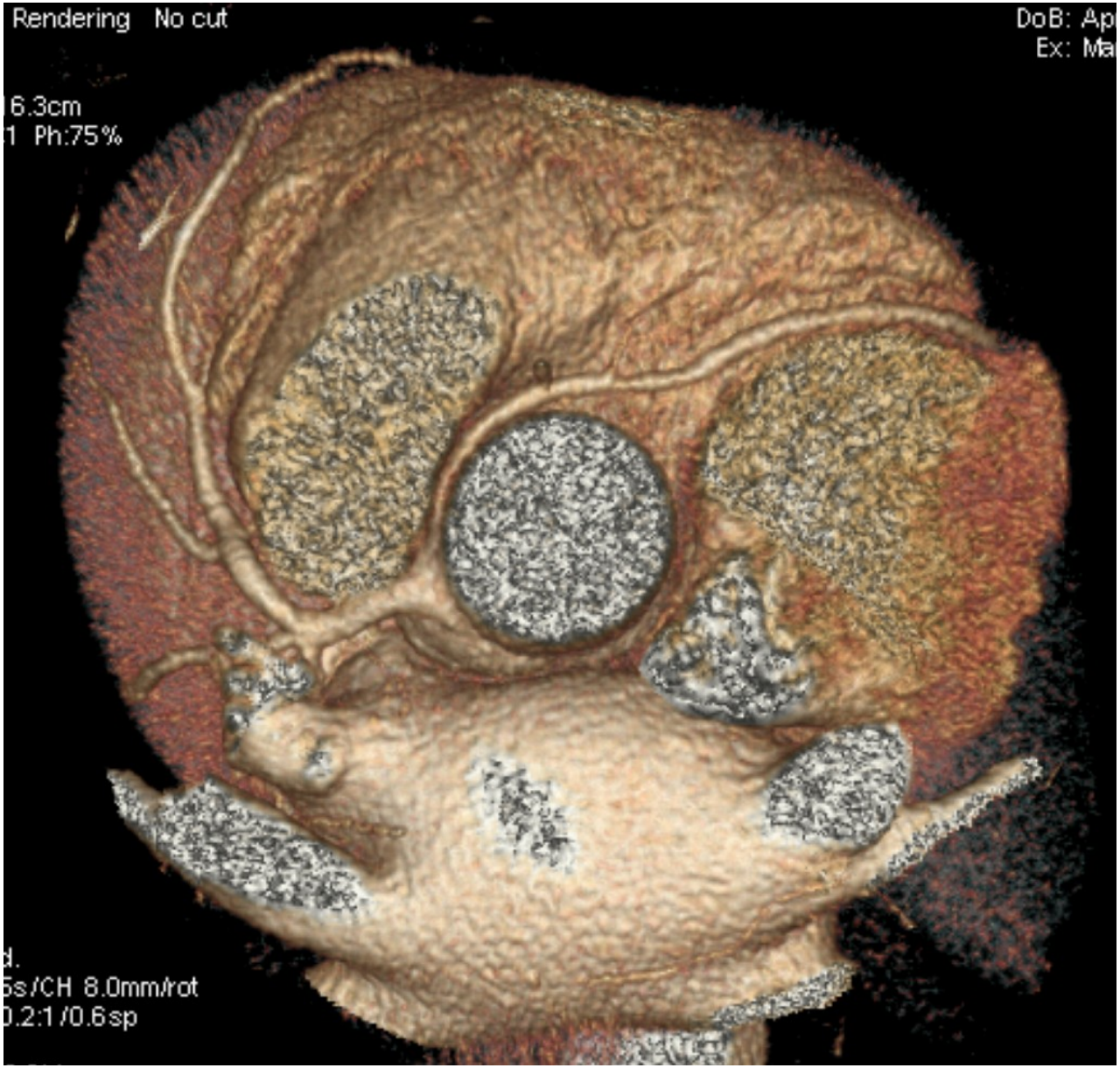
Rendering No cut
DoB: Ap
Ex: Ma
6.3cm
1 Ph:75%
d.
5s/CH 8.0mm/rot
0.2:1/0.6sp

Fistule coronaire

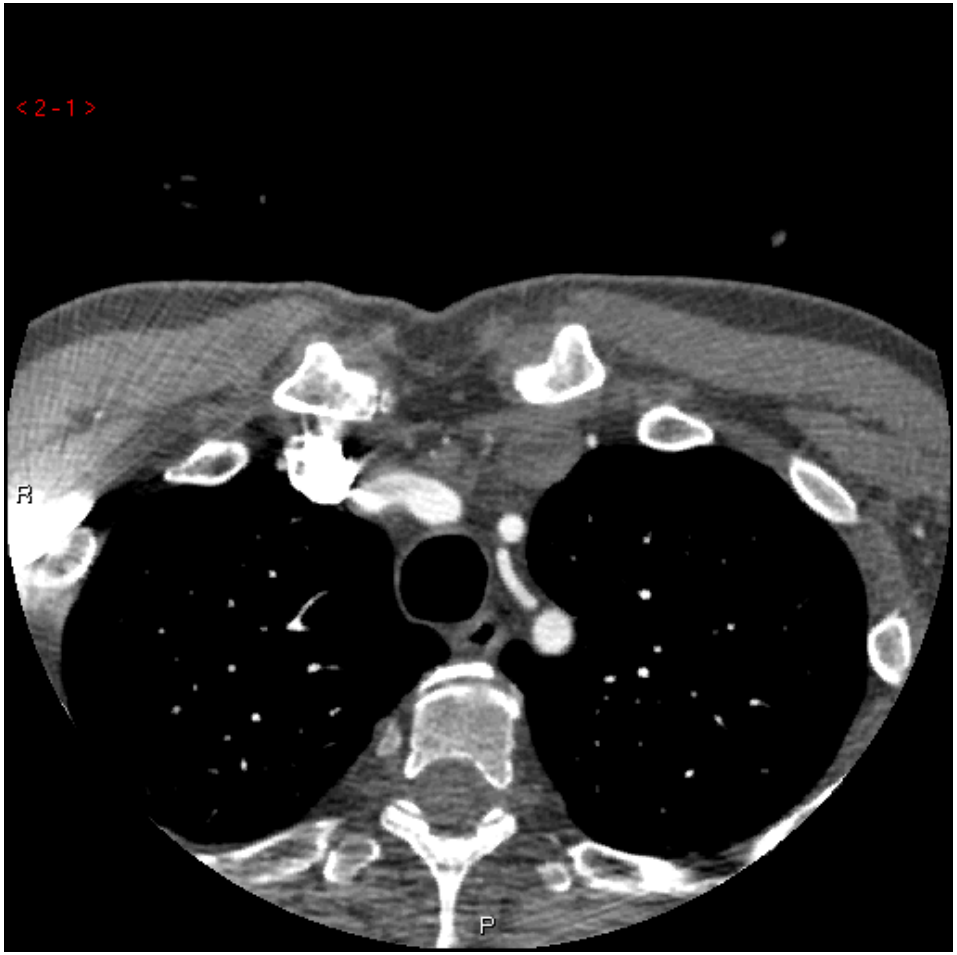

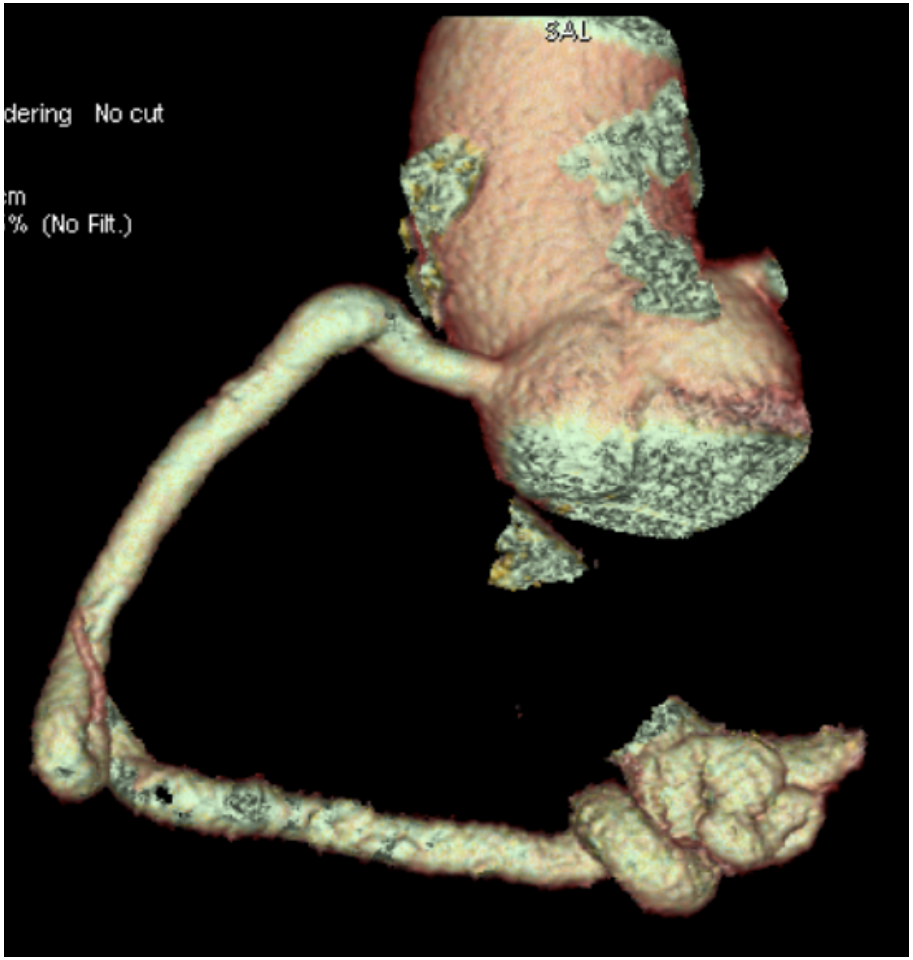

Conclusion

- IRM +++ ventricule droit
  - morphologique
  - Fonctionnel

- Scanner 2ème intention
  - Coronaires+++

- Suivi dans un centre spécialisé

Liste des Centres de Compétence M3C