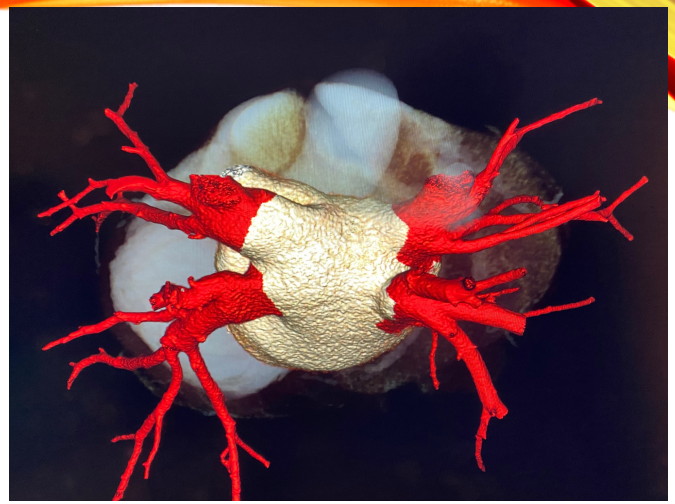

# VEINES PULMONAIRES EN SCANNER

Pr Luc Christiaens
Cardiologie
CHU de Poitiers

# VEINES PULMONAIRES EN TDM

- 3 grandes indications
  - Retour veineux pulmonaire anormal
  - Bilan avant ablation d' ACFA
  - Recherche de sténose de VP post ablation
- 2 réponses
  - Nombre de VP
  - Diamètres des ostia des VP
- 2 techniques
  - TDM injecté avec ou sans synchronisation / ECG

CPSD: VP supérieure droite
VPID: VP inférieure droite
VPSG: VP supérieure gauche
VPIG: VP inférieure gauche

# VP: SCANNER NON INJECTÉ

Aperçu des veines pulmonaires

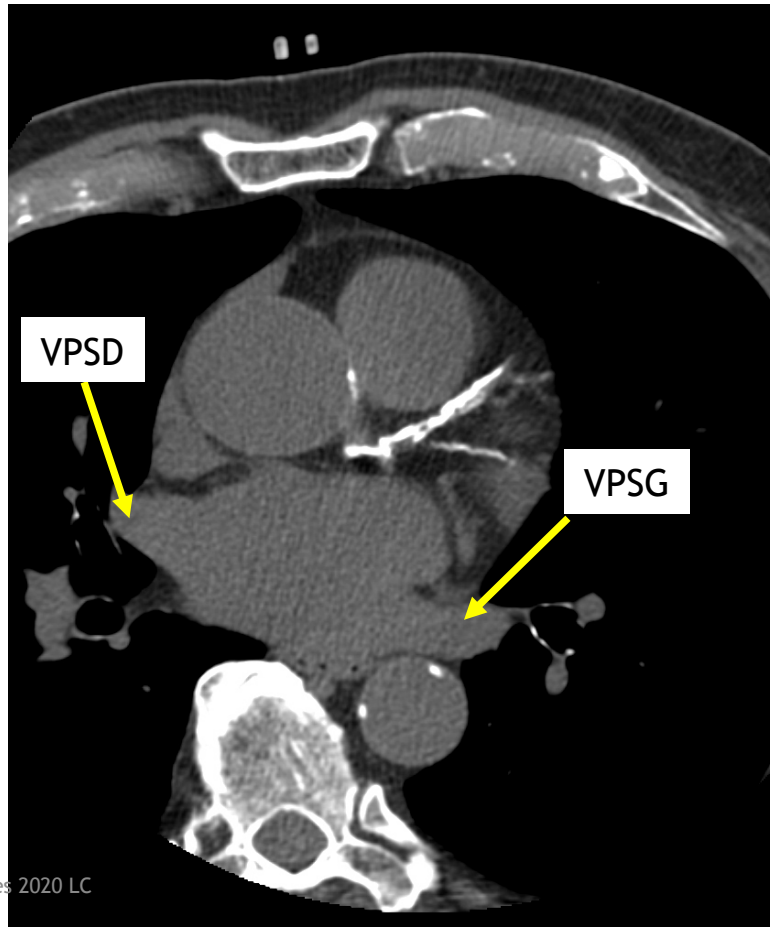


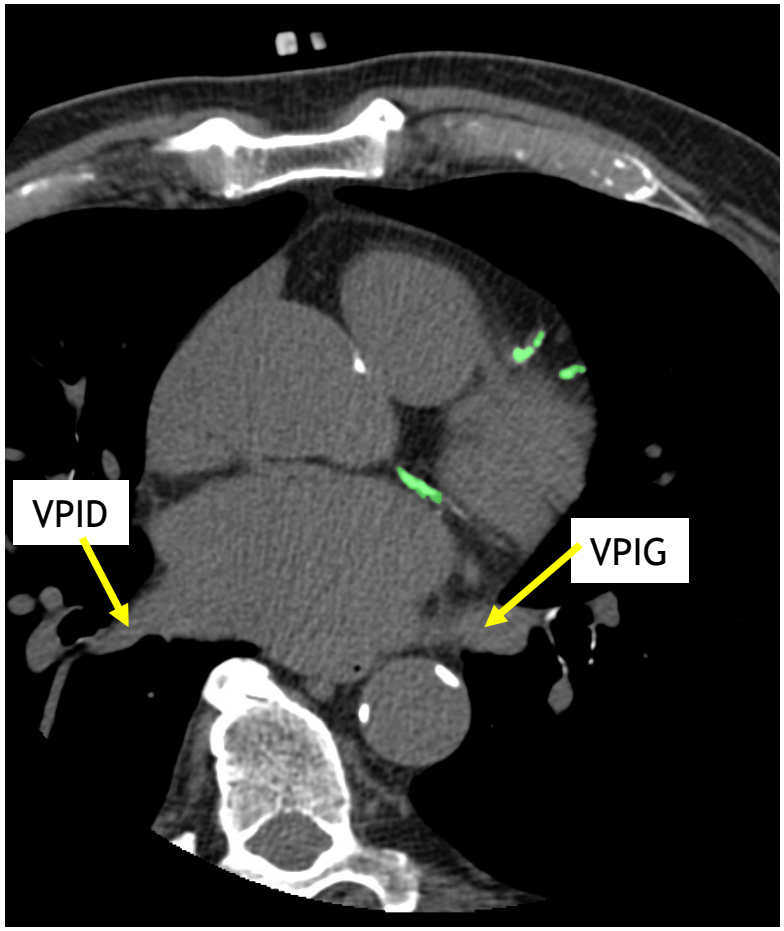

# VP: SCANNER INJECTÉ

- Même protocole que scanner des coronaires
- Réalisé essentiellement avant ablation de fibrillation atriale (FA)
- Permet de vérifier l'abouchement des VP (nombre et diamètres)
- Permet une évaluation des dimensions de l'OG (volume)
- Dépistage éventuel de thrombus OG (+/- temps tardif) (cf. cours auricule et scanner)
- Evaluation du réseau coronaire

# Segmentation automatique des veines pulmonaires

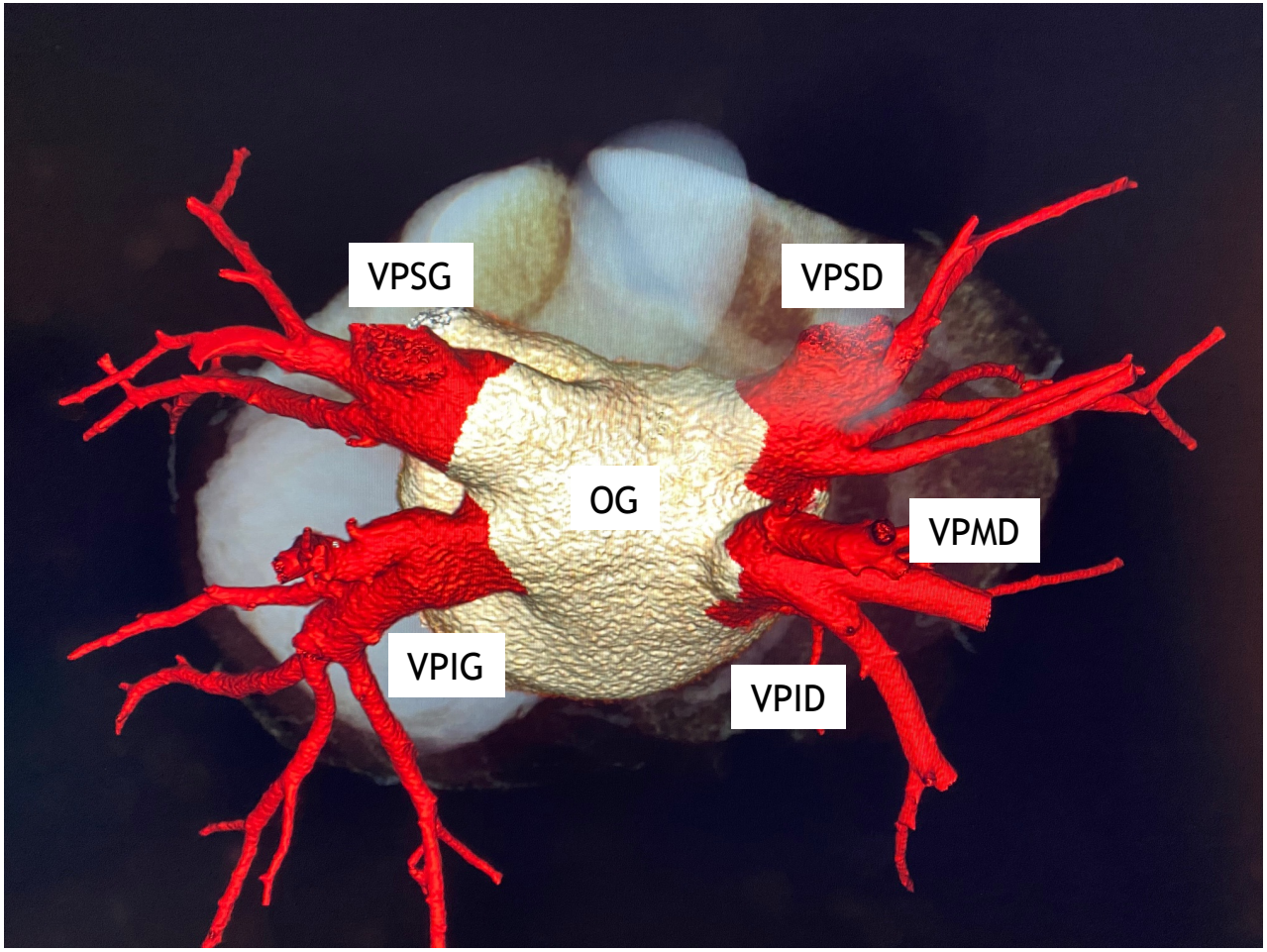

# VP: SCANNER INJECTÉ SYNCHRONISÉ / ECG

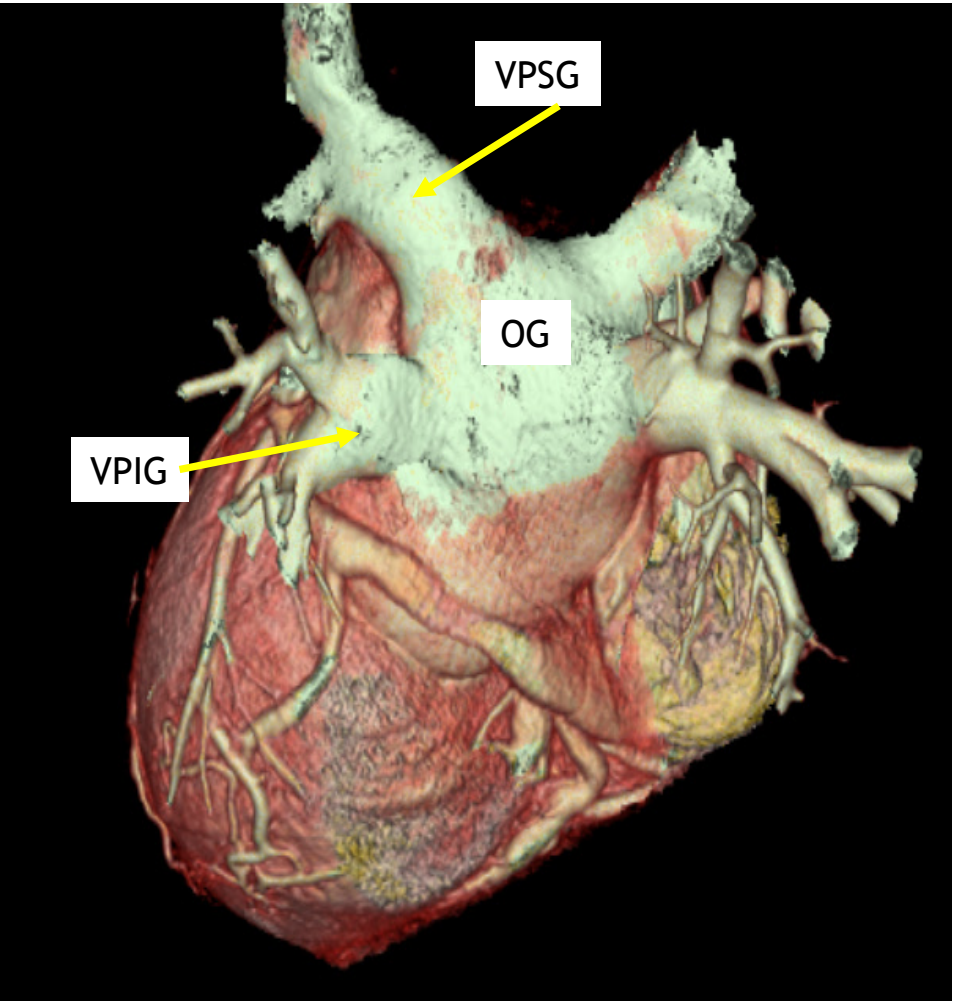


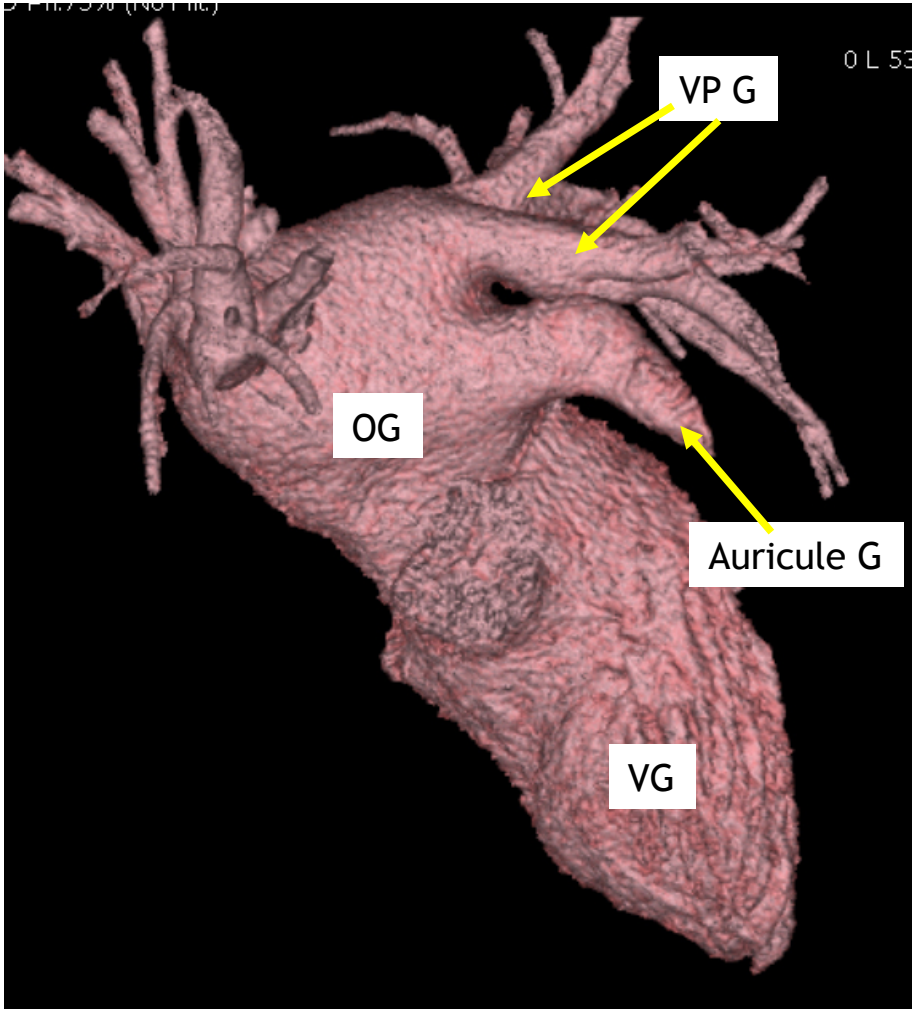

# NOMBRE DE VEINES PULMONAIRES

**Pulmonary Venous Drainage Patterns by Total Number of Pulmonary Veins**

Number with 6 veins or more = 0
Number with 5 veins = 21
  18 = Normal + MLPV
  1 = MLPV + accessory RIPV + CLT
  2 = Normal + accessory RIPV
Number with 4 veins = 170
  164 = Normal → 85%
  1 = RCT + MLPV draining into LA
  1 = LCT + MLPV draining into LA
  1 = RSPV to SVC + MLPV draining into LA
  3 = CLT + accessory RIPV
Number with 3 veins = 9
  1 = CRT
  8 = CLT
Number with 2 veins or less = 0

Nombre variable de VP

N = 200 patients avant ablation d' ACFA

Cronin P, Acad Radiol 2007

Oh YW, Eur J Radiol 2007

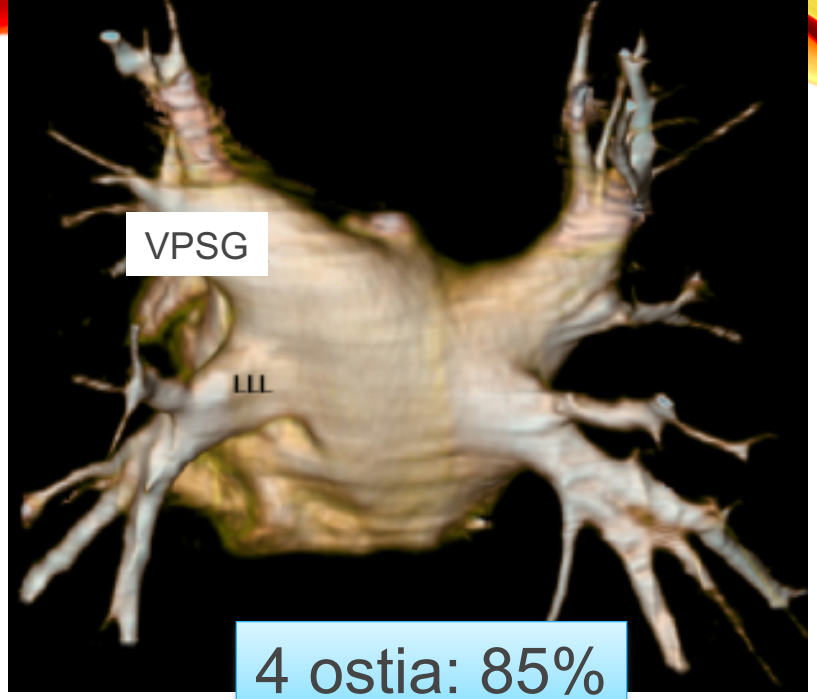


4 ostia: 85%

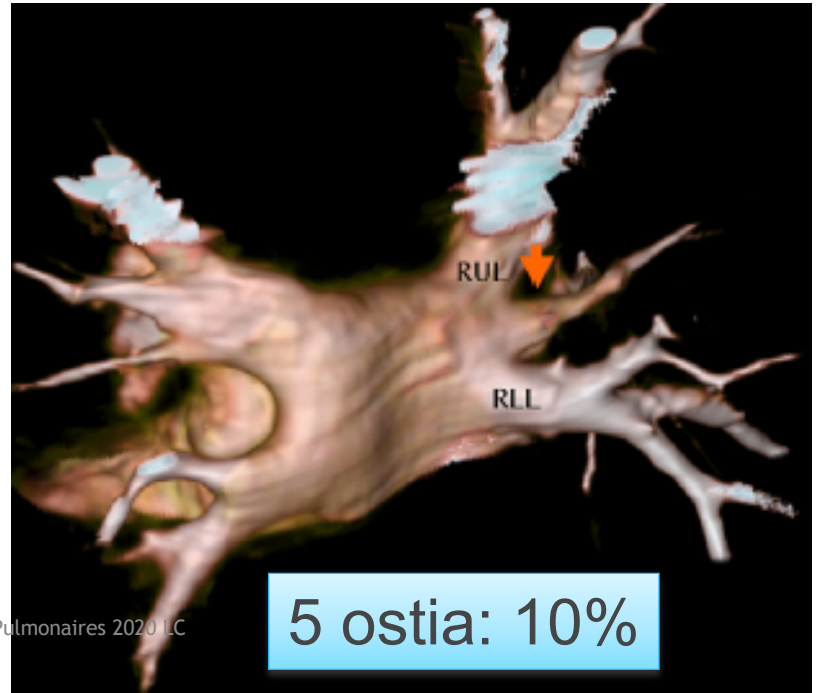


5 ostia: 10%

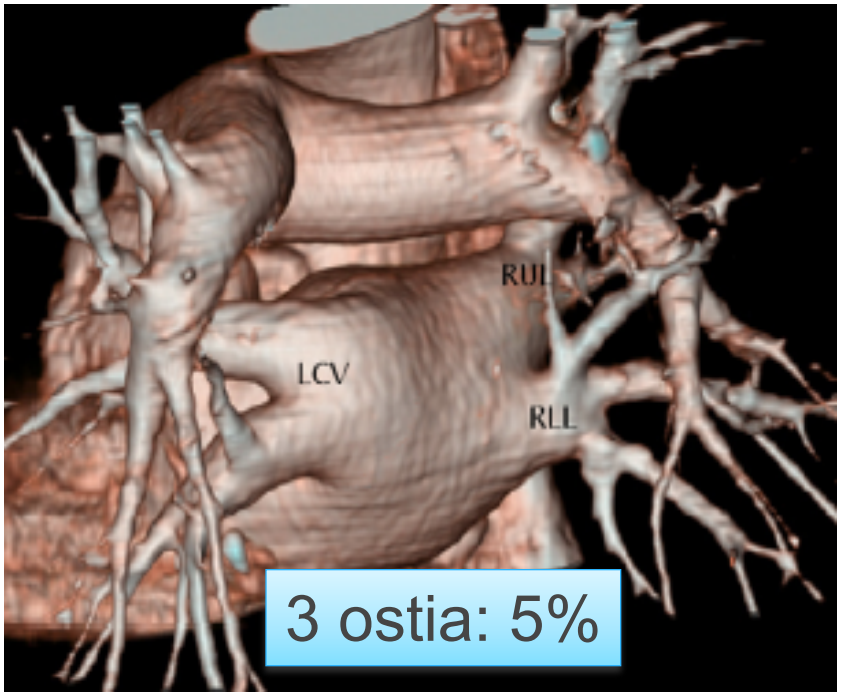


3 ostia: 5%

**Marom E M et al.**
**Radiology 2004;230:824-829**

# CLASSIFICATION

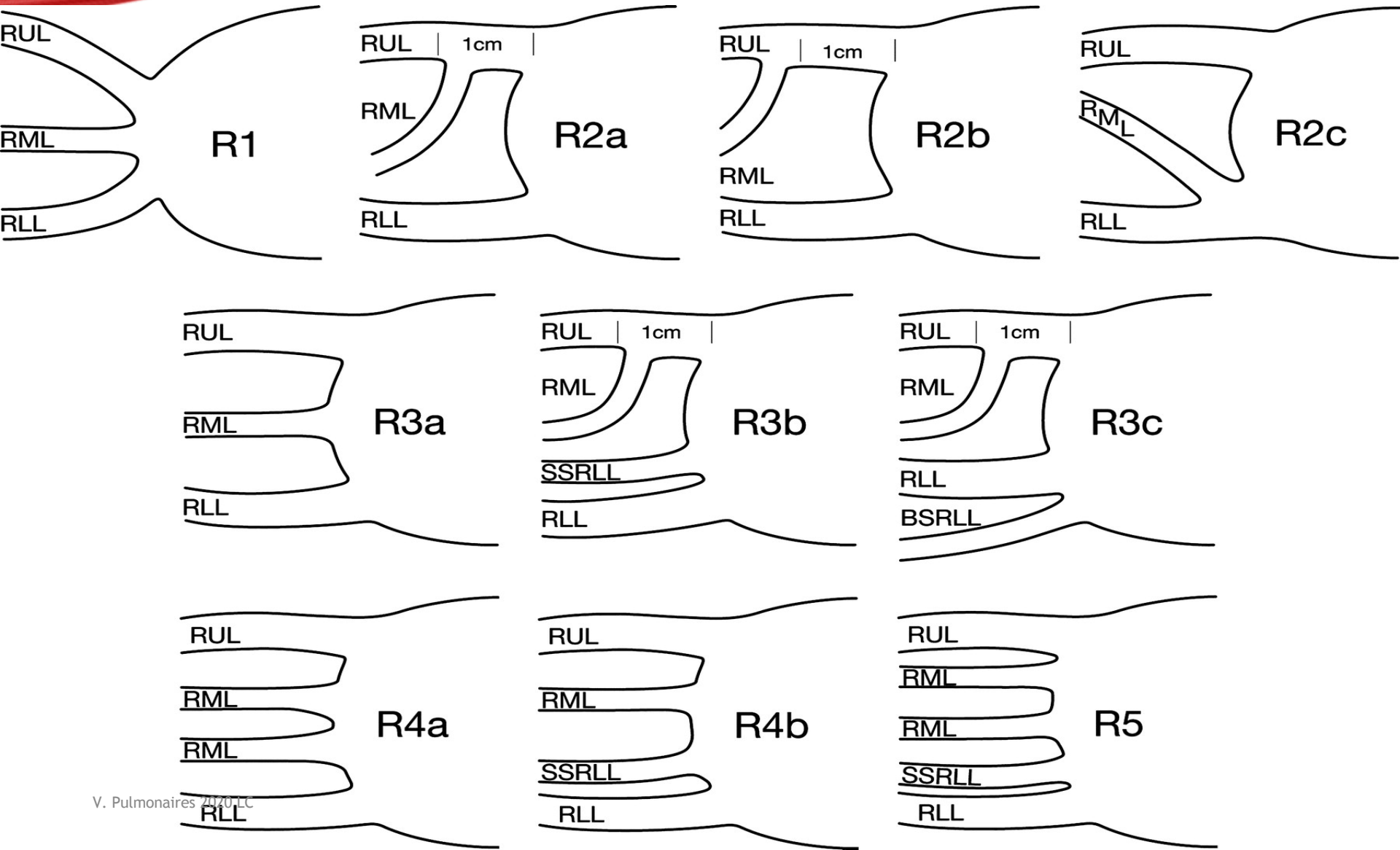

# CLASSIFICATION DES VP GAUCHES

**Marom E M et al.**
**Radiology 2004;230:824-829**

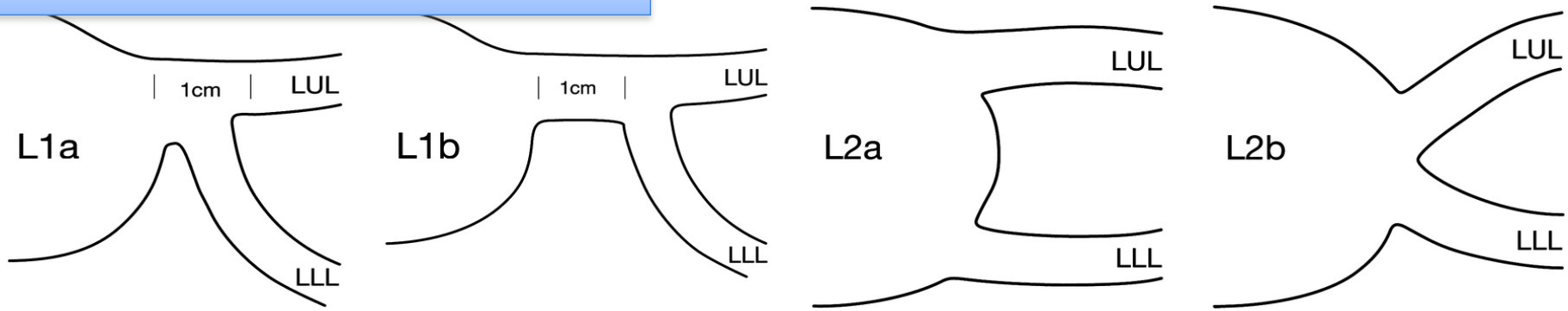


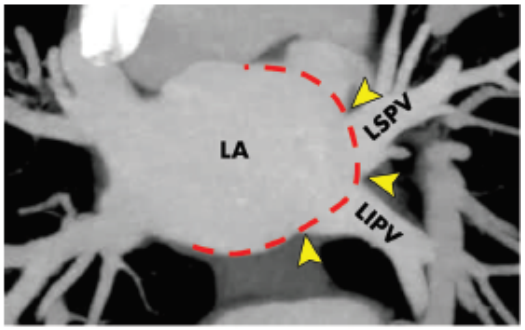


a.

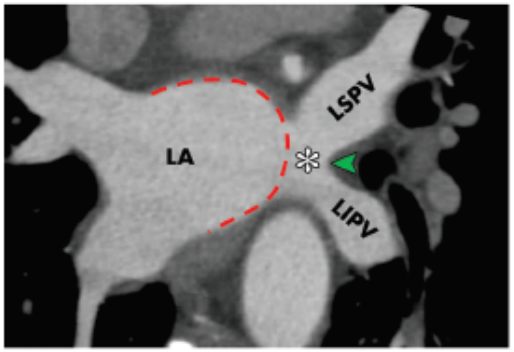


Ostium séparé ou commun

Hassani C. RadioGraphics 2017

# EXEMPLES

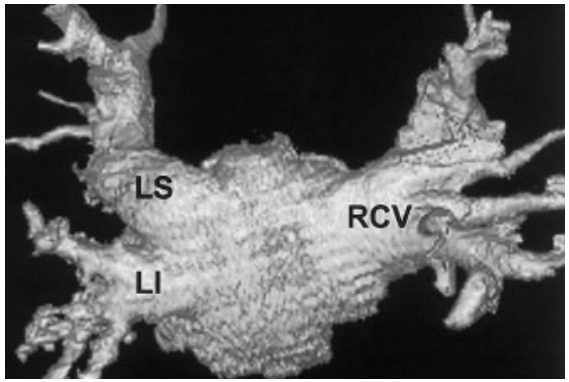


Right common PV

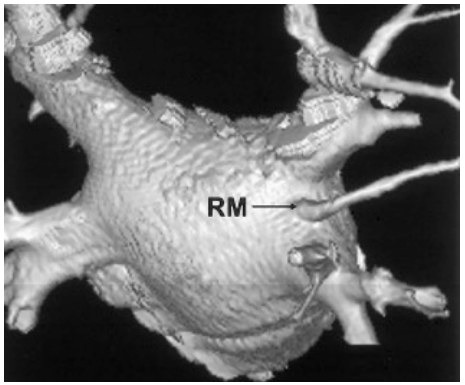


Right middle lobe PV

Superior segment
Right lower lobe PV

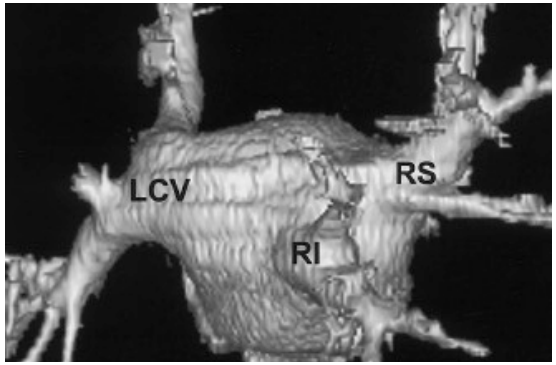


Left common PV

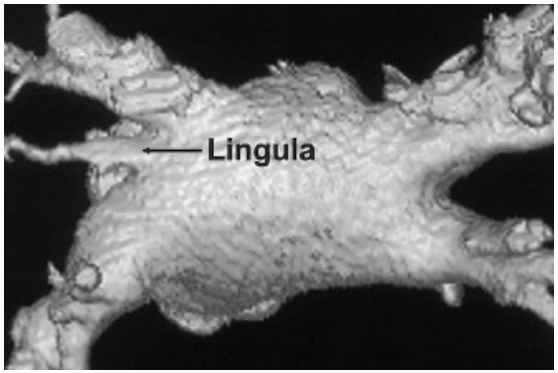


Lingula PV



Lacomis 2003 Radiographics

# IMPACT DU NOMBRE DE VP

Attention à l'oubli de petite VP entrainant des échecs d'ablation de FA

Summary of the drainage pattern of PVs and clinical findings in patients with AF

| Drainage pattern of PVs | Number of patients | Recurrence after first RFCA | Ectopic AF foci from variant PV (no. of patients) | Second RFCA | Success after second RFCA |
|---|---|---|---|---|---|
| Four PVs with separate ostia | 97(82.9%) | 23 | | 9 | 2 |
| Additional single RMPV[a] | 13(11.0%) | + (1) | + (2) | 1 | 1 |
| Additional two RMPVs and superior segment PV of RLL | 1(0.9%) | – | – | – | |
| Additional two LLPVs | 1(0.9%) | – | – | – | |
| Additional Lt. lingular segment PV | 1(0.9%) | + | + | 1 | 1 |
| Left common PV | 4(3.4%) | – | + (4) | – | |
| Total | 117 | 25 (21.4%) | | 11 | 4 |

[a] An additional RMPV that had a separate orifice; RMPV = right middle lobe PV; LLPV = left lower lobe PV; RLL = right lower lobe.

Oh YW, Eur J Radiol 2007

# ENDOSCOPIE VIRTUELLE

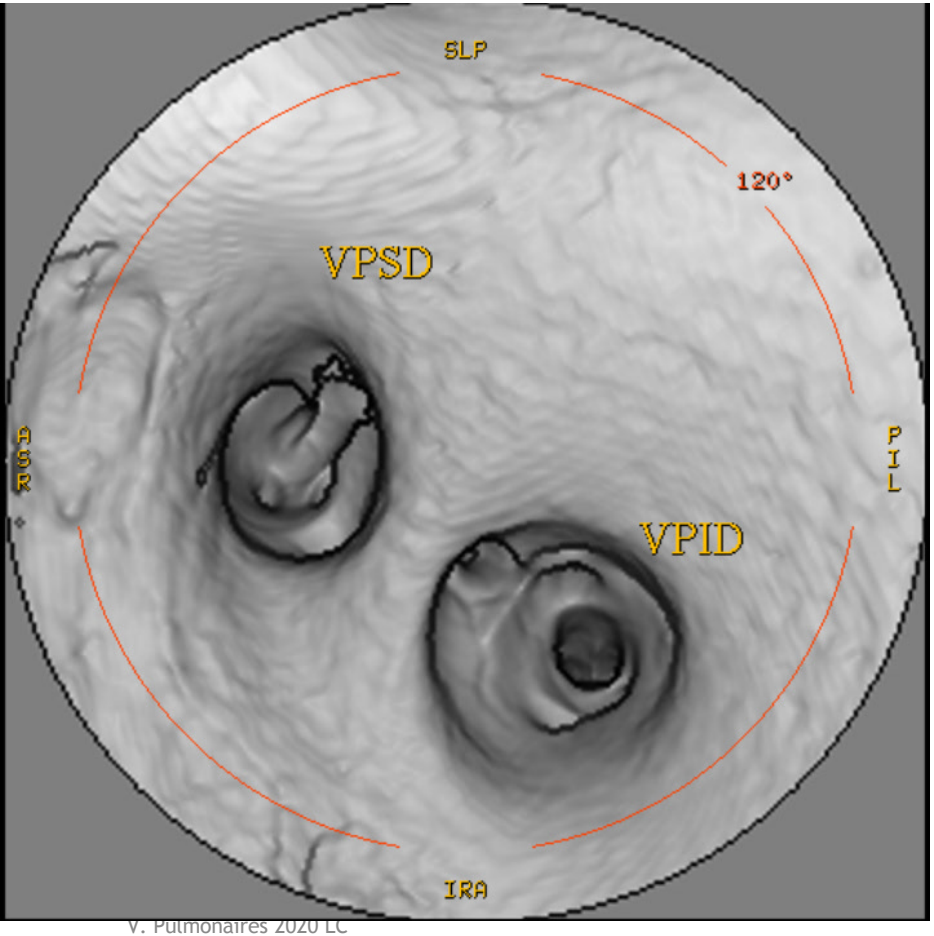


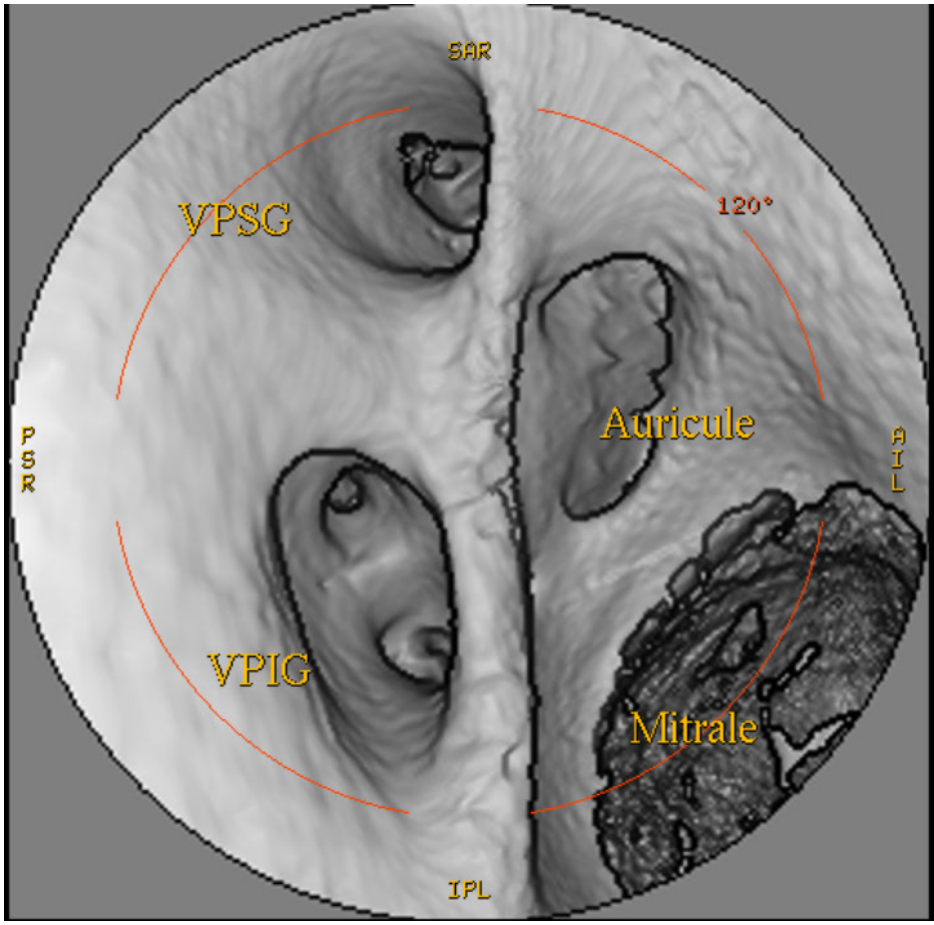

# MESURES DES DIAMÈTRES DE VP

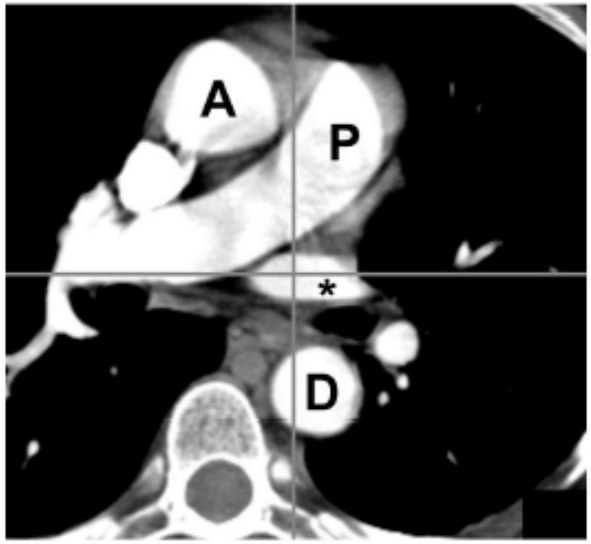


Axial

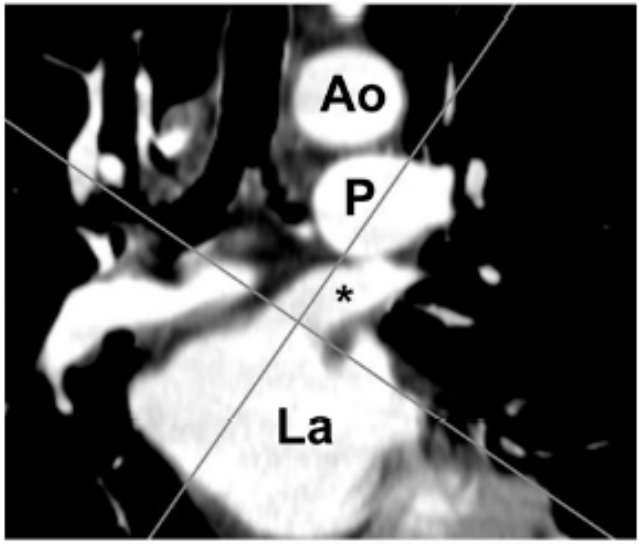


Coronal

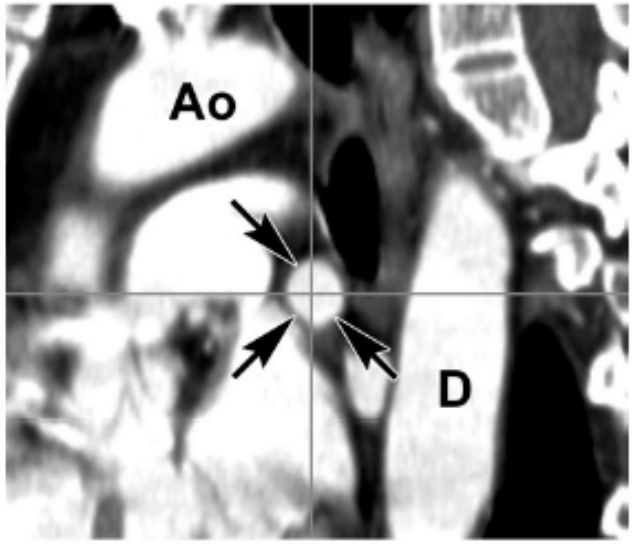


Oblique

Kim YH, Radiology 2005

# Veines pulmonaires droites
# (homme 56 ans sans ACFA)

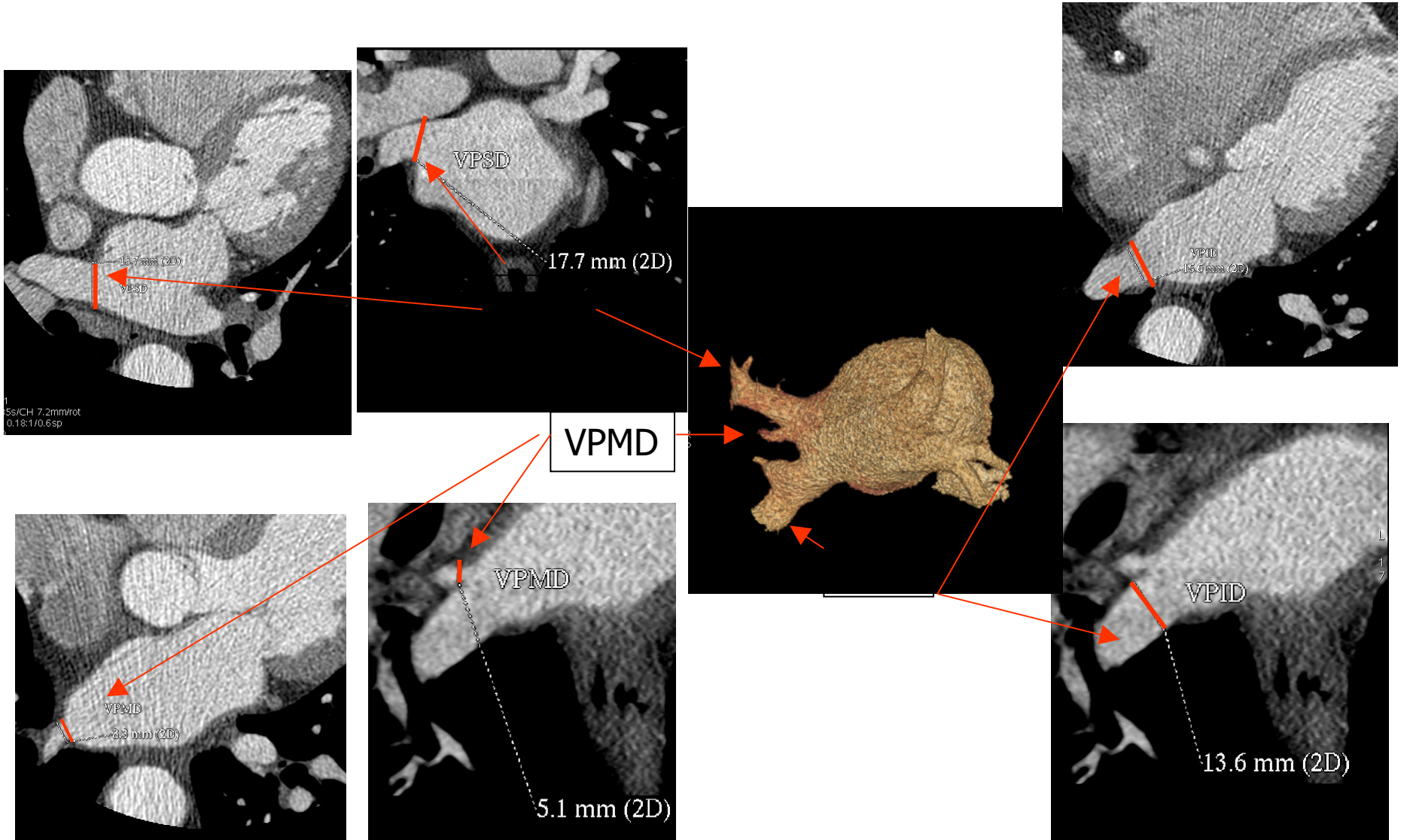

# DIAMÈTRE DES VEINES PULMONAIRES

Attention: diamètres variables / cycle cardiaque, conditions de charge …

**Table 2.** Measurements of Ostia Pulmonary Veins: MSCT Versus ICE

| | MSCT AP Diameters (mm) | MSCT SI Diameters (mm) | ICE Diameters (mm) | AP Diameter MSCT vs. ICE p Value | SI Diameter MSCT vs. ICE p Value |
|---|---|---|---|---|---|
| LSPV | 14.6 ± 3.0 | 19.0 ± 3.8* | 14.3 ± 3.9 | NS | <0.01 |
| LIPV | 12.8 ± 3.0 | 17.1 ± 2.9* | 14.3 ± 3.0 | <0.01 | <0.01 |
| Both LPV | 13.7 ± 3.1 | 18.0 ± 3.5* | 14.3 ± 3.5 | NS | <0.01 |
| RSPV | 16.5 ± 3.2 | 19.2 ± 2.8* | 15.9 ± 4.7 | NS | <0.01 |
| RIPV | 16.6 ± 3.9 | 18.2 ± 3.7* | 15.4 ± 4.3 | NS | <0.01 |
| Both RPV | 16.6 ± 3.6 | 18.7 ± 3.3* | 15.7 ± 4.5 | NS | <0.01 |
| LCO | 20.4 ± 7.5 | 26.8 ± 6.8* | 24.3 ± 3.9 | NS | NS |
| RCO | 25.9 ± 7.5 | 33.5 ± 7.6* | 21.6 ± 7.3 | NS | <0.05 |
| Additional RPV | 7.4 ± 1.6 | 7.6 ± 2.0 | 8.5 ± 1.8 | NS | <0.05 |
| Additional LPV | 11.0 | 10.1 | — | — | — |
| All PV | 15.1 ± 3.6 | 18.4 ± 3.4* | 14.9 ± 4.0 | NS | <0.01 |



Jongbloed M, J Am Coll Cardiol 2005

# DIAMÈTRE DES VEINES PULMONAIRES

Attention: diamètres variables / cycle cardiaque, conditions de charge …

En moyenne:

| Pulmonary Vein | Mean Diameter (mm) |
|---|---|
| Right superior pulmonary vein | 16.4–18.4 |
| Right inferior pulmonary vein | 15.5–17.4 |
| Left superior pulmonary vein | 15.9–18.0 |
| Left inferior pulmonary vein | 13.4–15.5 |

Habituellement les VP droites sont plus larges que les gauches et la VPSD est la plus large de toutes
Pour plus de détails cf. diapos suivantes …

**TABLE 1**
**Measured Values for Pulmonary Vein Diameter, Cross-sectional Area, and Roundness**

| Vein and Location* | Diameter (mm) | | | Cross-sectional Area ($mm^2$) | | | Roundness | | |
|---|---|---|---|---|---|---|---|---|---|
| | Mean | SD | 95% CI | Mean | SD | 95% CI | Mean | SD | 95% CI |
| RSPV | | | | | | | | | |
| Level 1 | 11.9 | 2.5 | 11.4, 12.4 | 132.2 | 52.1 | 122.2, 142.2 | 0.87 | 0.13 | 0.85, 0.90 |
| Level 2 | 10.6 | 2.1 | 10.2, 11.0 | 109.5 | 38.9 | 102.1, 117.0 | 0.83 | 0.11 | 0.81, 0.85 |
| Level 3 | 10.0 | 1.7 | 9.7, 10.3 | 95.3 | 29.7 | 89.6, 101.0 | 0.85 | 0.10 | 0.83, 0.87 |
| Level 4 | 9.2 | 1.7 | 8.9, 9.5 | 81.9 | 27.0 | 76.7, 87.1 | 0.83 | 0.11 | 0.81, 0.85 |
| Level 5 | 8.6 | 1.7 | 8.3, 8.9 | 72.9 | 26.1 | 67.9, 77.9 | 0.82 | 0.12 | 0.80, 0.85 |
| Level 6 | 7.9 | 1.8 | 7.5, 8.2 | 61.0 | 26.3 | 56.0, 66.1 | 0.84 | 0.11 | 0.82, 0.86 |
| LSPV | | | | | | | | | |
| Level 1 | 10.0 | 2.2 | 9.6, 10.5 | 106.5 | 41.2 | 98.6, 114.4 | 0.77 | 0.15 | 0.74, 0.80 |
| Level 2 | 9.6 | 2.0 | 9.1, 9.8 | 94.2 | 35.7 | 87.3, 101.1 | 0.77 | 0.14 | 0.74, 0.80 |
| Level 3 | 9.6 | 2.0 | 9.2, 10.0 | 93.2 | 32.1 | 87.1, 99.4 | 0.79 | 0.14 | 0.77, 0.82 |
| Level 4 | 9.3 | 1.8 | 9.0, 9.7 | 89.9 | 30.3 | 84.1, 95.7 | 0.78 | 0.13 | 0.76, 0.81 |
| Level 5 | 9.0 | 2.0 | 8.6, 9.4 | 82.4 | 30.8 | 76.5, 88.3 | 0.80 | 0.13 | 0.78, 0.83 |
| Level 6 | 8.3 | 2.0 | 7.9, 8.7 | 69.4 | 31.5 | 63.4, 75.5 | 0.83 | 0.12 | 0.80, 0.85 |
| RIPV | | | | | | | | | |
| Level 1 | 12.7 | 2.0 | 12.3, 13.1 | 142.6 | 42.6 | 134.5, 150.8 | 0.90 | 0.09 | 0.89, 0.92 |
| Level 2 | 11.2 | 2.2 | 10.7, 11.6 | 112.4 | 39.7 | 104.8, 120.0 | 0.90 | 0.10 | 0.88, 0.92 |
| Level 3 | 10.5 | 9.7 | 8.7, 12.4 | 84.5 | 35.0 | 77.8, 91.3 | 0.90 | 0.10 | 0.88, 0.91 |
| Level 4 | 8.1 | 1.9 | 7.7, 8.4 | 60.2 | 27.3 | 55.0, 65.4 | 0.89 | 0.08 | 0.88, 0.91 |
| Level 5 | 6.9 | 1.7 | 6.6, 7.3 | 45.1 | 21.4 | 41.0, 49.3 | 0.88 | 0.12 | 0.86, 0.91 |
| Level 6 | 6.0 | 1.6 | 5.7, 6.3 | 34.4 | 16.0 | 31.4, 37.5 | 0.86 | 0.14 | 0.84, 0.89 |
| LIPV | | | | | | | | | |
| Level 1 | 9.4 | 2.2 | 9.0, 9.9 | 98.0 | 34.1 | 91.4, 104.6 | 0.74 | 0.16 | 0.71, 0.77 |
| Level 2 | 9.6 | 2.3 | 9.1, 10.0 | 99.0 | 33.8 | 92.5, 105.5 | 0.74 | 0.15 | 0.71, 0.77 |
| Level 3 | 9.9 | 2.2 | 9.5, 10.4 | 101.0 | 36.5 | 94.0, 108.0 | 0.80 | 0.15 | 0.77, 0.83 |
| Level 4 | 9.6 | 2.1 | 9.2, 10.1 | 91.9 | 35.5 | 85.1, 98.8 | 0.83 | 0.12 | 0.81, 0.85 |
| Level 5 | 8.8 | 2.1 | 8.4, 9.1 | 73.4 | 33.3 | 67.0, 79.8 | 0.87 | 0.13 | 0.85, 0.90 |
| Level 6 | 7.6 | 2.0 | 7.2, 7.9 | 55.1 | 26.6 | 50.0, 60.2 | 0.87 | 0.12 | 0.84, 0.89 |

Note.—CI = confidence interval, LIPV = left inferior pulmonary vein, LSPV = left superior pulmonary vein, RIPV = right inferior pulmonary vein, RSPV = right superior pulmonary vein, SD = standard deviation.

* Six locations of measurement were used, 5 mm apart, from the ostium (level 1) to 25 mm beyond the ostium (level 6).

Kim YH. Radiology 2005

**TABLE 2**
**Mean Values for Pulmonary Vein Diameter and Cross-sectional Area Stratified according to Sex**

| Vein and Location* | Diameter (mm) | | | Cross-sectional Area ($mm^2$) | | |
|---|---|---|---|---|---|---|
| | Men | Women | *P* Value | Men | Women | *P* Value |
| RSPV | | | .195 | | | .056 |
| Level 1 | 12.2 | 11.8 | | 147.9 | 124.0 | |
| Level 2 | 11.1 | 10.4 | | 121.6 | 103.2 | |
| Level 3 | 10.2 | 9.9 | | 102.2 | 91.6 | |
| Level 4 | 9.3 | 9.1 | | 85.4 | 80.1 | |
| Level 5 | 8.8 | 8.5 | | 79.2 | 69.6 | |
| Level 6 | 8.3 | 7.6 | | 68.8 | 57.0 | |
| LSPV | | | <.006 | | | <.003 |
| Level 1 | 10.6 | 9.8 | | 117.1 | 100.9 | |
| Level 2 | 10.2 | 9.0 | | 106.5 | 87.7 | |
| Level 3 | 10.3 | 9.2 | | 103.0 | 88.1 | |
| Level 4 | 9.8 | 9.1 | | 94.6 | 87.4 | |
| Level 5 | 9.4 | 8.8 | | 88.5 | 79.1 | |
| Level 6 | 8.8 | 8.1 | | 78.3 | 64.7 | |
| RIPV | | | .554 | | | .521 |
| Level 1 | 12.8 | 12.6 | | 148.2 | 139.7 | |
| Level 2 | 11.1 | 11.2 | | 114.4 | 111.3 | |
| Level 3 | 9.7 | 11.0 | | 89.9 | 81.7 | |
| Level 4 | 8.3 | 8.0 | | 64.4 | 58.0 | |
| Level 5 | 7.0 | 6.9 | | 48.8 | 43.2 | |
| Level 6 | 6.1 | 5.9 | | 36.5 | 33.4 | |
| LIPV | | | .498 | | | .565 |
| Level 1 | 9.5 | 9.4 | | 97.5 | 98.3 | |
| Level 2 | 9.2 | 9.8 | | 95.4 | 100.9 | |
| Level 3 | 9.9 | 10.0 | | 104.1 | 99.4 | |
| Level 4 | 9.9 | 9.5 | | 97.4 | 89.0 | |
| Level 5 | 9.0 | 8.6 | | 77.8 | 71.0 | |
| Level 6 | 7.8 | 7.4 | | 58.9 | 53.1 | |

Note.—LIPV = left inferior pulmonary vein, LSPV = left superior pulmonary vein, RIPV = right inferior pulmonary vein, RSPV = right superior pulmonary vein.

* Six locations of measurement were used, 5 mm apart, from the ostium (level 1) to 25 mm beyond the ostium (level 6).

Author's personal copy

Kim YH
Radiology 2005

**Comparison of Pulmonary Vein Ostial Diameters by Gender**

| | Mean Pulmonary Vein Diameter | | |
|---|---|---|---|
| | Men | Women | *P* Value |
| Right superior pulmonary vein | 17.8 | 16.7 | .13 |
| Left superior pulmonary vein | 16.7 | 15.9 | .13 |
| Middle lobe pulmonary vein | 8.6 | 8.2 | .14 |
| Right inferior pulmonary vein | 17.3 | 15.9 | .04 |
| Left inferior pulmonary vein | 15.1 | 13.4 | .007 |



Cronin P, Acad Radiol 2007

## Mean Pulmonary Vein Ostial Diameters

| Superior and Inferior Pulmonary Vein Ostial Diameters (mm) | | | | | |
|---|---|---|---|---|---|
| | Minimum | Mean | Maximum | SD | 95% CI |
| All SPV | 6.00 | 17.00 | 30.00 | 4.12 | 16.70–17.50 |
| RSPV | 6.00 | 17.63 | 30.00 | 4.36 | 17.02–18.23 |
| LSPV | 9.00 | 16.56 | 26.70 | 3.80 | 16.03–17.08 |
| All IPV | 5.20 | 15.90 | 28.20 | 3.78 | 15.50–16.30 |
| RIPV | 8.50 | 17.06 | 28.20 | 3.50 | 16.58–17.55 |
| LIPV | 5.20 | 14.76 | 23.50 | 3.70 | 14.25–15.27 |

| Middle Lobe Pulmonary Vein Ostial Diameter (mm) | | | | | |
|---|---|---|---|---|---|
| | Minimum | Mean | Maximum | SD | 95% CI |
| All MLPV | 3.00 | 8.56 | 14.00 | 2.16 | 8.27–8.86 |
| Drain to RSPV | 3.00 | 8.50 | 14.00 | 2.10 | 8.27–8.82 |
| Drain to RIPV | 5.00 | 8.82 | 13.00 | 2.09 | 7.58–10.05 |
| Drain to LA | 4.00 | 8.60 | 14.00 | 2.67 | 7.50–9.73 |

| Other Pulmonary Vein Ostial Diameters (mm) | | | | | |
|---|---|---|---|---|---|
| | Minimum | Mean | Maximum | SD | 95% CI |
| Common trunks | 12.00 | 24.29 | 44.00 | 7.45 | 20.52–28.06 |
| Accessory veins | 6.00 | 7.70 | 9.70 | 1.44 | 6.60–8.91 |

V. Pulmonaires 2020 LC

# RETOUR VEINEUX PULMONAIRE ANORMAL

- Chez l' adulte
  - RVPA partiel et CIA type sinus venosus
  - Avant chirurgie

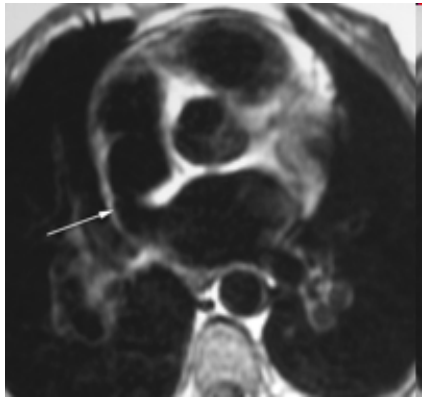

- IRM
- Scanner injecté sans synchronisation
  - Habituellement suffisant

Cf. cours sur les cardiopathies congénitales en scanner et IRM et article de Hassani C RadioGraphics 2017

# CURIOSITÉS

Diverticule accessoire de l' OG
20% des TDM

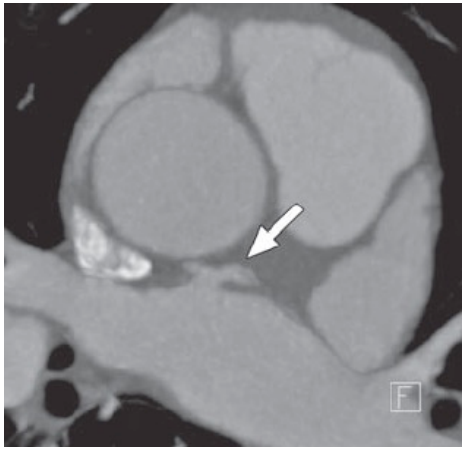

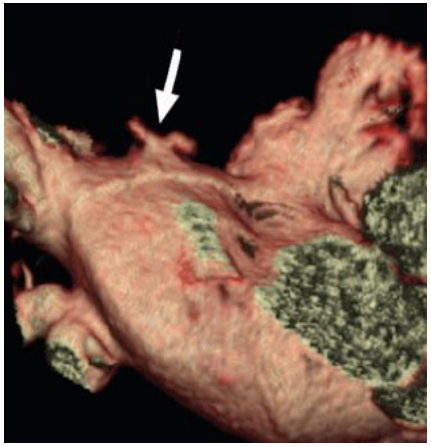

Abbara S
2009 AJR

Auricule Gauche accessoire
8% des TDM

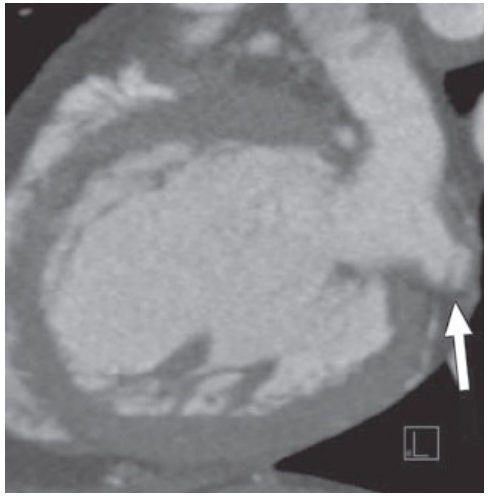

# BILAN AVANT ABLATION D' ACFA

- Indication fréquente
- Patients en rythme sinusal ou non
- Repérage, mesure des veines pulmonaires
- Analyse OG et auricule gauche
  - Volume
  - Thrombus éventuel
  - Forme de l'auricule G

# FUSION D' IMAGES

## SCANNER /CARTOGRAPHIE MAGNÉTIQUE (CORDIS®)

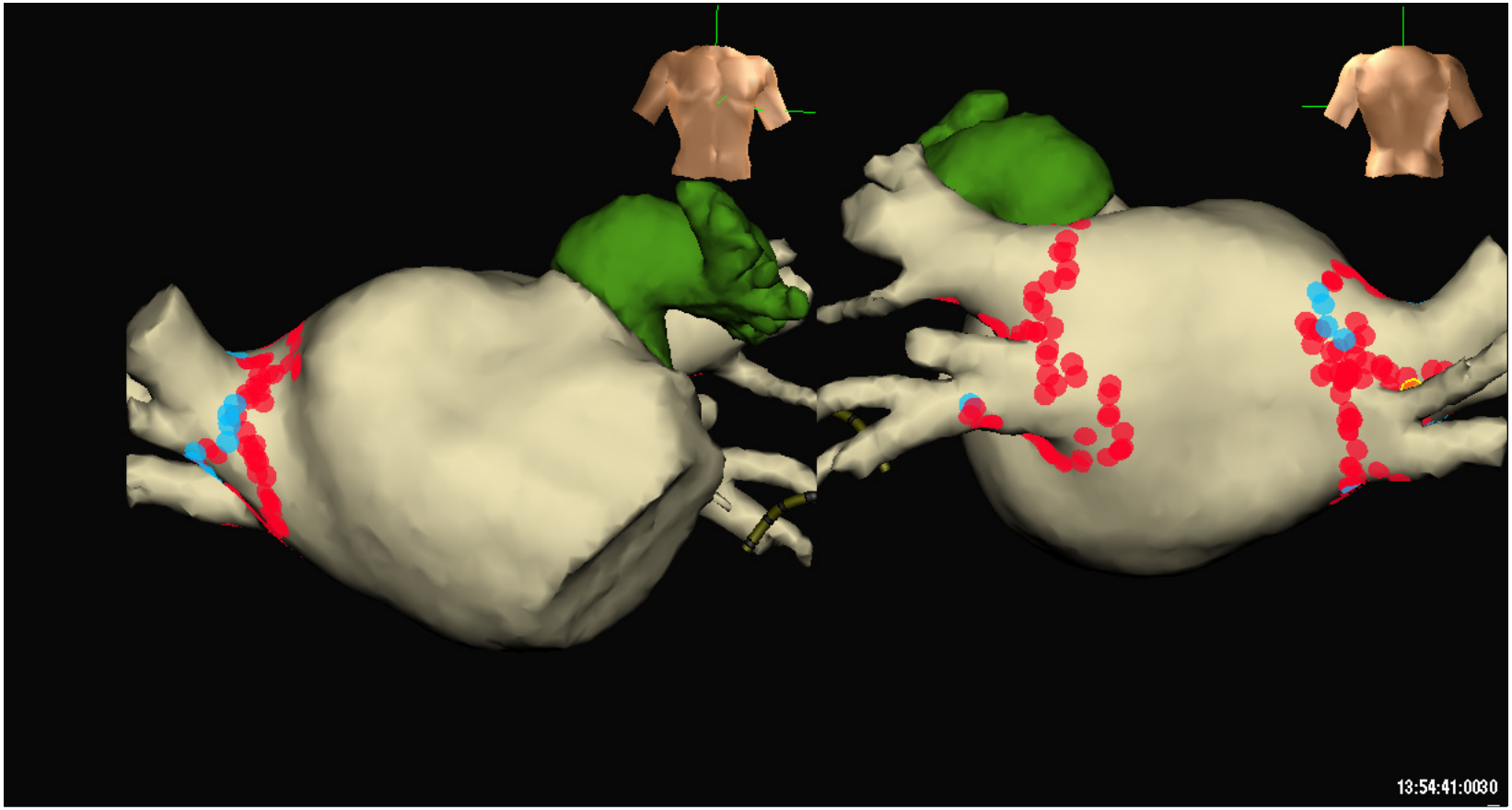

# STÉNOSE DE VEINE PULMONAIRE

Burgsthaler C, Int J Cardiol 2005

Sténose serrée de la VPSG à J3 post ablation ACFA

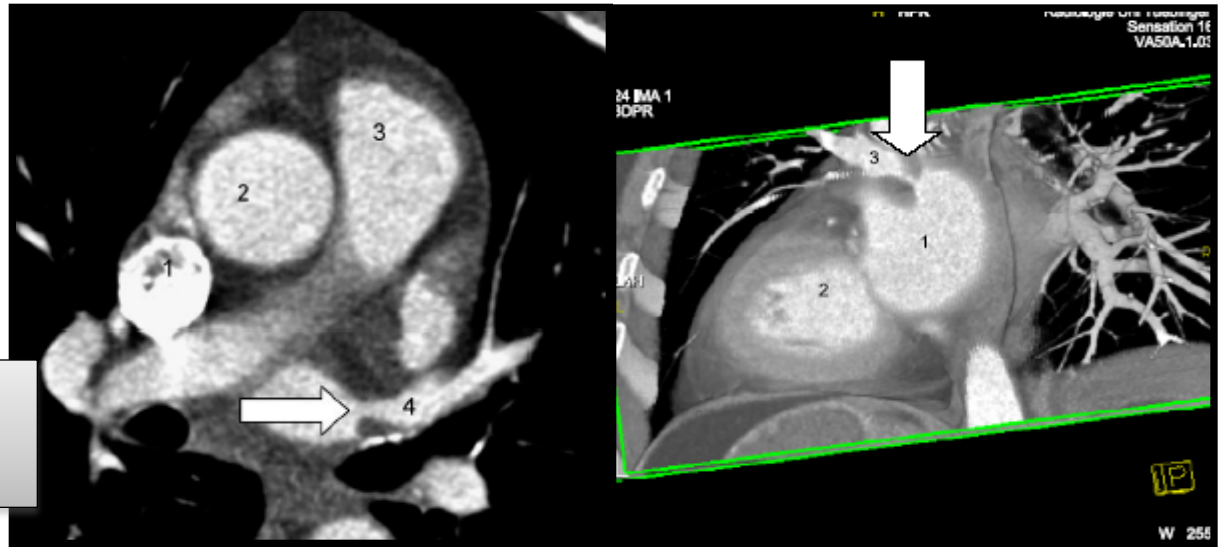


Évolution à 3 mois

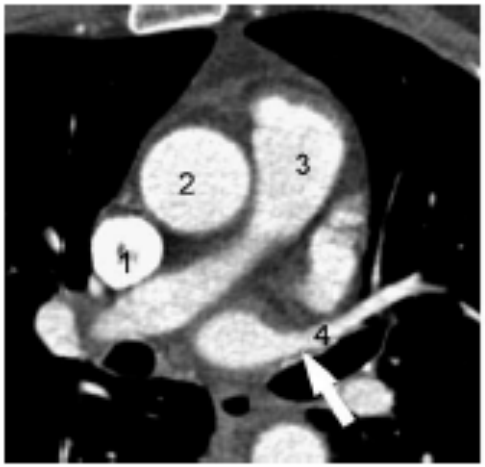


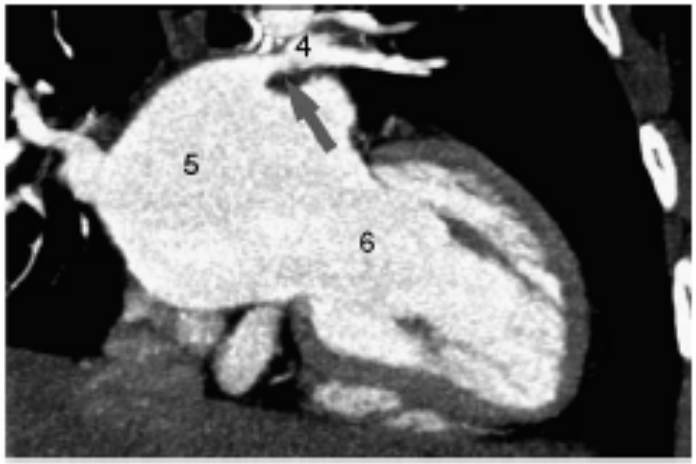

# IRM APRÈS ABLATION DE FA

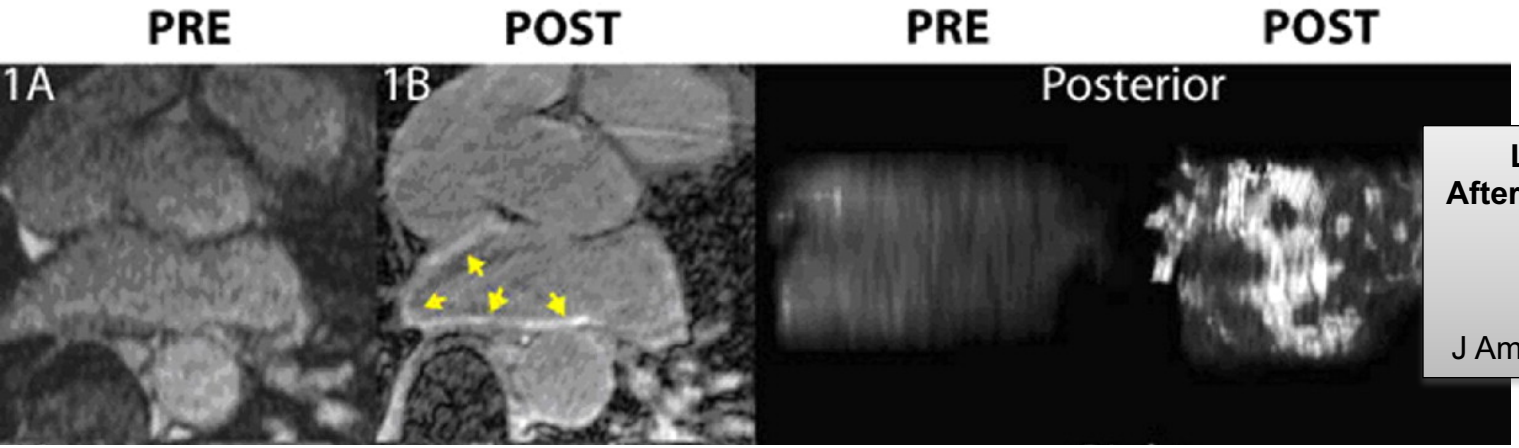


**LA Injury Before and After Catheter Ablation for AF**

Tops L. F.
J Am Coll Cardiol CVImg 2009

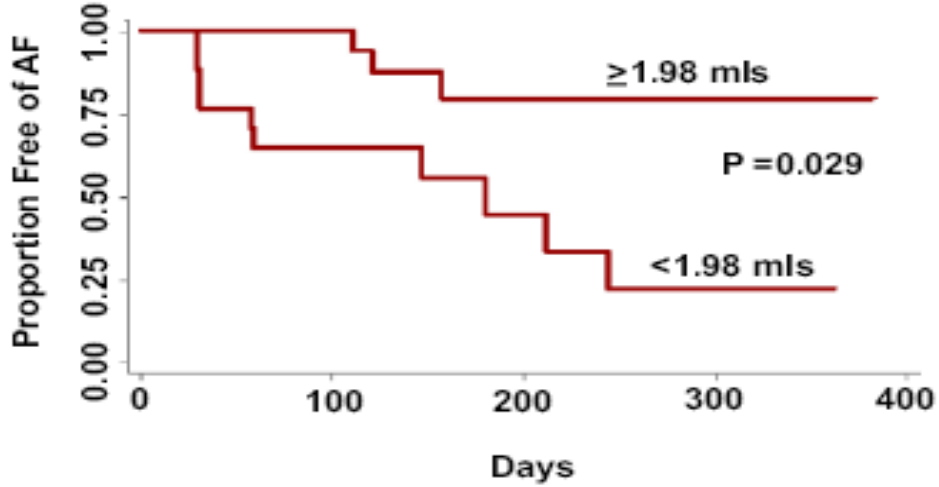


**Figure 3.** Kaplan-Meier AF Free Survival Curve Stratified by RIPV Scar

Analyse de la fibrose atriale gauche

Peters DC JACC Cv Img 2009

# FIBROSE ATRIALE POST ABLATION

- DECAAF (Delayed-Enhancement MRI Determinant of Successful Radiofrequency Catheter Ablation of Atrial Fibrillation) LGE-MRI PROTOCOL

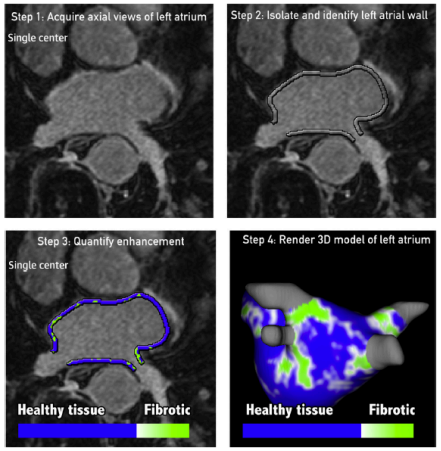


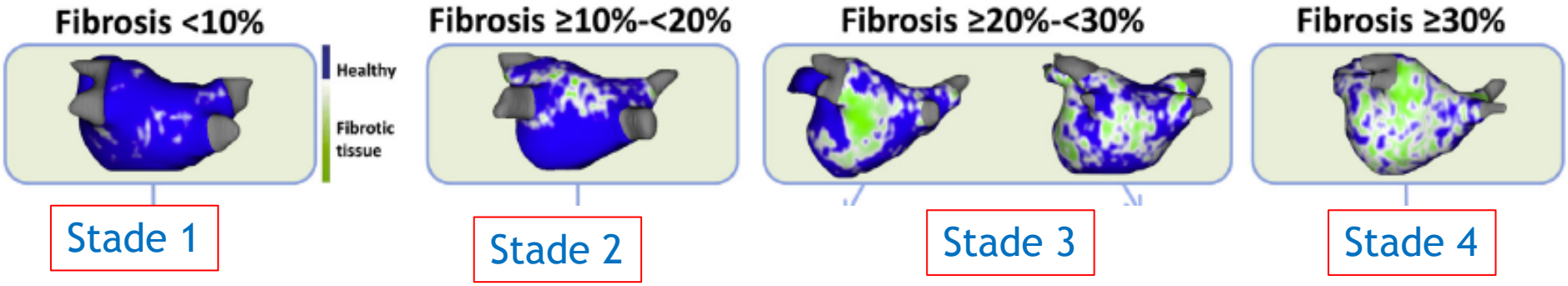


Classification UTAH: réhaussement / volume global atrial G



Siebermair J. J Am Coll Cardiol EP 2017;3:791-802

# A RETENIR

- Variabilité des veines pulmonaires
- Ne pas négliger les petites VP
- Comprendre la fusion d'image scanner et cartographie électromagnétique
- Recherche de fibrose atriale post ablation de FA

# RÉFÉRENCES


- Marom EM, et al. Variations in Pulmonary Venous Drainage to the Left Atrium: Implications for Radiofrequency Ablation. Radiology 2004;230:824-9
- Hassani C, Saremi F. Comprehensive Cross-sectional Imaging of the Pulmonary Veins. RadioGraphics 2017;37:1928-54
- Kiuchi K, et al. Topographic variability of the left atrium and pulmonary veins assessed by3D-CT predicts the recurrence of atrial fibrillation after catheter ablation. Journal of Arrhythmia 2015;31:286–292
- Appelbaum E and Manning WJ. Left Atrial Fibrosis by Late Gadolinium Enhancement Cardiovascular Magnetic Resonance Predicts Recurrence of Atrial Fibrillation After Pulmonary Vein Isolation. Do You See What I See? Circ Arrhythm Electrophysiol. 2014;7:2-4
- Galizia M, et al. Radiologic review of acquired pulmonary vein stenosis in adults. Cardiovasc Diagn Ther2018 Jun; 8(3): 387–398
- Siebermair J, et al. Assessment of left atrial fibrosis by late Gadolinium enhancement magnetic resonance imaging. Methodology and clinical implications. J Am Coll Cardiol EP 2017;3:791-802